

# Sudden visual loss after football game: a case report

Chui Yin Chua<sup>1</sup>, Wan Hazabbah Wan Hitam<sup>1</sup>, Zabri Kamarrudin<sup>2</sup>, Ronald Arun Das<sup>2</sup>,  
Poh Yan Ong<sup>2</sup>

<sup>1</sup>Department of Ophthalmology, School of Medical Sciences, Universiti Sains Malaysia, 16150 Kubang Kerian, Kelantan, Malaysia

<sup>2</sup>Department of Ophthalmology, Hospital Selayang, Malaysia

**Correspondence to:** Chui Yin Chua. Department of Ophthalmology, School of Medical Sciences, Universiti Sains Malaysia, 16150 Kubang Kerian, Kelantan, Malaysia. chuiyin@gmail.com

Received: 2010-07-05 Accepted: 2011-01-10

## Abstract

• We describe a 27-year-old gentleman who presented with sudden loss of left vision after a football match. As there was no improvement with previous treatment, he was referred to us for second opinion three weeks after initial presentation. Examination showed a quiet left eye with large whitish lesion with fluid level in the macula. It posed a dilemma in diagnosis as possibility of infectious cause could not be ruled out. Pars plana vitrectomy with vitreous biopsy was done and it showed old organised blood from premacular haemorrhage resulted from valsalva retinopathy.

• **KEYWORDS:** valsalva retinopathy; football; premacular haemorrhage

DOI:10.3969/j.issn.1672-5123.2011.02.05

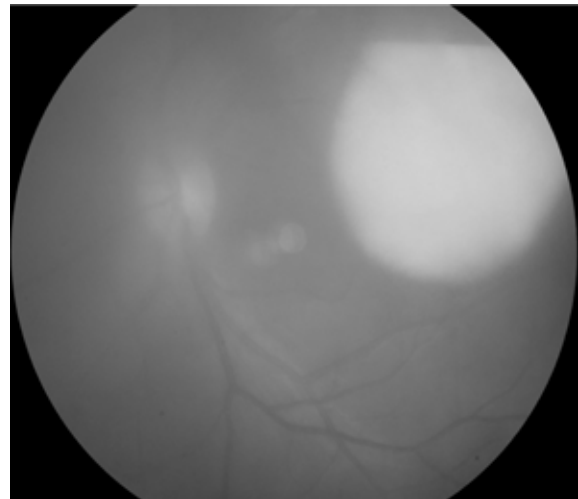
Chua CY, Hitam WHW, Kamarrudin Z, Das RA, Ong PY. Sudden visual loss after football game: a case report. *Guoji Yanke Zazhi (Int J Ophthalmol)* 2011;11(2):214-215

## INTRODUCTION

Valsalva retinopathy is first described in 1972 by Thomas Duane as a particular form of retinopathy, preretinal and haemorrhagic in nature that occurs secondary to a sudden increase in intrathoracic pressure. The pressure is transmitted to the eye which causes a sharp rise in intraocular venous pressure and spontaneous rupture of retinal capillaries, leading to a sudden, painless loss of vision in an otherwise healthy eye. The characteristic of premacular haemorrhage in valsalva retinopathy is typically described to be under the internal limiting membrane (ILM) or subhyaloid, or both.

## CASE REPORT

A healthy 27-year-old gentleman presented to general ophthalmologist with the complaint of sudden painless reduction of left central vision during a football game. There was no direct trauma to the eye. He was diagnosed to have left anterior uveitis with a posterior pole lesion and treated as toxoplasmosis. He was referred to our centre three weeks after



**Figure 1** Left eye fundus shows distinct border whitish lesion with fluid level.

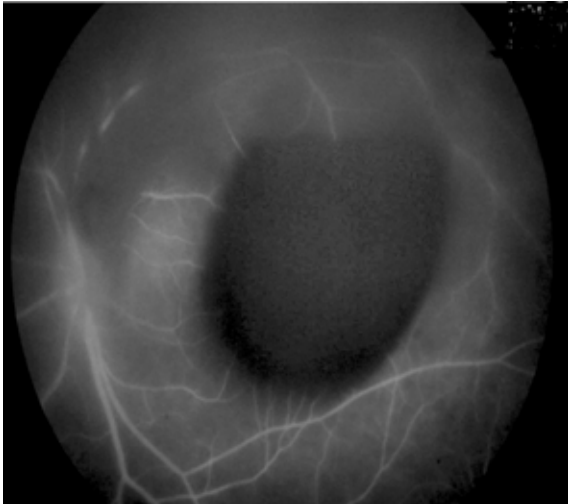
his initial presentation as there was no improvement clinically. Systemically he was otherwise well. He works in a farm dealing with chicken droppings for production of organic fertilizer.

Ophthalmic examination showed best-corrected visual acuity of 6/6 in the right eye and counting fingers at 2 feet in the affected eye. Fundus examination of the left eye revealed a distinct border whitish lesion with fluid level of about 3 optic disc diameters overlying the macula (Figure 1). There was surrounding mild vitritis. However, there was no evidence of vasculitis, retinitis or choroiditis. Examination of right eye showed normal findings.

In this patient, the provisional diagnosis was old premacular haemorrhage from various causes. However, choroidal abscess with possible infectious endophthalmitis was also considered. He works in a farm and some organism e. g. *Nocardia spp* from the soil can present as choroidal abscess<sup>[1,2]</sup>.

Fundus fluorescein angiography (FFA) was performed revealed a masking effect caused by the preretinal lesion and there was no evidence of vasculitis, retinitis or choroiditis (Figure 2). Optical coherence tomography (OCT) showed a lesion with high reflectivity at the macula, suggestive of preretinal haemorrhage. Blood investigation of diabetic screening, bleeding disorder, septic workup for the possibility of endogenous infection was normal.

He underwent left pars plana vitrectomy with vitreous biopsy. Intraoperatively, it was noted that the fluid collection was actually old organised blood. Postoperative vision subsequently improved to 6/6. Vitreous fluid analysis showed presence of old red blood cell and culture and sensitivity



**Figure 2 FFA of left fundus-masking effect caused by preretinal lesion with no evidence of vasculitis, choroiditis and retinitis.**

showed no growth of organism.

#### DISCUSSION

This patient had premacular haemorrhage secondary to valsalva retinopathy. It was reported in healthy adults following wide range of activities including blowing ballon<sup>[3]</sup>, pregnancy<sup>[4]</sup>, colonoscopy<sup>[5]</sup> etc. Those with diabetes, sickle cell, blood disorder are at increased risk<sup>[6]</sup>. Valsalva retinopathy has a predilection for the macula as it is presumed that the perifoveal capillary bed has detailed structural architecture.

The treatment of valsalva retinopathy usually suffices with observation alone. For those with large macular subhyaloid haemorrhage (more than three disc diameters in size), laser membranotomy is another option<sup>[7,8]</sup>. This method causes immediate drainage of the haemorrhage into the inferior vitreous cavity and out of the visual axis. Hence, patient will have rapid return of central visual acuity. In this case, vitrectomy was done to evacuate the blood.

In conclusion, valsalva maneuvers can cause retinal haemorrhages. To our knowledge, this is the first report of valsalva retinopathy associated with football game. However,

the diagnosis should only be made after excluding other causes of retinal haemorrhages, or in this case, infective cause as the lesion mimics retinal or choroidal abscess. Most cases of valsalva retinopathy in previous healthy eye will only require conservative management.

#### REFERENCES

- 1 Haripriya A, Lalitha P, Mathen M, Prajna NV, Kim R, Shukla D, Natchiar G, Srinivasan M. Nocardia endophthalmitis after cataract surgery: clinicomicrobiological study. *Am J Ophthalmol* 2005;139(5):837-846
- 2 Mishra SK, Damodaran VN. Observations on the natural habitats of *Cryptococcus neoformans* and *Nocardia asteroides*. *Indian J Chest Dis* 1973;15(4):263-271
- 3 Georgiou T, Pearce IA, Taylor RH. Valsalva retinopathy associated with blowing ballons. *Eye* 1999;13(5):686-687
- 4 Al-Mujaini AS, Montana CC. Valsalva retinopathy in pregnancy: a case report. *JMed case reports* 2008;2:101
- 5 Lee VY, Liu DT, Chan WM, Lam DS. Valsalva retinopathy as a complication of colonoscopy. *J Clin Gastroenterol* 2005;39(7):643
- 6 Konotey-Ahulu F. Valsalva vitreous haemorrhage and retinopathy in sickle cell haemoglobin C disease. *Lancet* 1997;349(9067):1774
- 7 Raymond LA. Neodymium: YAG laser treatment for haemorrhages under the internal limiting membrane and posteriorhyaloid face in the macula. *Ophthalmology* 1995;102(3):406-411
- 8 Nili AAM, Lasheyi AR, Karkhaneh R, Maanaviat MR, Amimi A, Razaghi A, Alami Z. ND YAG laser application in premacular subhyaloid hemorrhage. *Arch Iranian Med* 2004;7(3):206-209

#### 足球比赛后突然视力丧失 1 例

Chui Yin Chua<sup>1</sup>, Wan Hazabbah Wan Hitam<sup>1</sup>, Zabri Kamarrudin<sup>2</sup>, Ronald Arun Das<sup>2</sup>, Poh Yan Ong<sup>2</sup>

(作者单位:<sup>1</sup> 马来西亚吉兰丹, 马来西亚理科大学医学院眼科; <sup>2</sup> 马来西亚 Selayang 医院眼科)

通讯作者: Chui Yin Chua. chuiyin@gmail.com

#### 摘要

患者,男,27岁,足球比赛后左眼突然视力丧失,由于初步治疗没有好转,患者于首次就诊3wk后再次就诊。检查发现左眼黄斑区大块白色病变以及积液。由于无法排除感染的可能性,这对于诊断提出了难题。玻璃体切除及活检显示为由于Valsalva视网膜病变导致的黄斑部视网膜前出血而形成的旧的血液。

**关键词:** Valsalva 视网膜病变; 足球; 黄斑部视网膜前出血