

The effect of single dose of brimonidine-purite 0.15% on choroidal thickness in healthy volunteers

Suleyman Demircan¹, Gökçen Gokce², Mustafa Atas¹, Ahmet Gülhan¹, Burhan Başkan¹, Gokmen Zararsiz³

¹Kayseri Training and Research Hospital, Eye Clinic, Kayseri 38010, Turkey

²Department of Ophthalmology, Kayseri Military Hospital, Kayseri 38010, Turkey

³Department of Biostatistics, Erciyes University, Kayseri 38010, Turkey

Correspondence to: Gokcen Gokce. Kayseri Training and Research Hospital, Eye Clinic, Kayseri 38010, Turkey. dr. s. demircan@hotmail.com

Received: 2017-02-03 Accepted: 2017-08-21

单剂量0.15%酒石酸溴莫尼定对正常个体脉络膜厚度的影响

Suleyman Demircan¹, Gökçen Gokce², Mustafa Atas¹, Ahmet Gulhan¹, Burhan Baskan¹, Gokmen Zararsiz³

(作者单位:¹38010 土耳其,开塞利,开塞利医疗研究医院,眼科;²38010 土耳其,开塞利,开塞利军事医院,眼科;³38010 土耳其,开塞利,埃尔吉耶斯大学,生物统计学系)

通讯作者:Gokcen Gokce. dr. s. demircan@hotmail.com

摘要

目的:通过使用频域相干光学断层深度增强成像测量正常个体脉络膜厚度(CT)以评估眼部使用0.15%酒石酸溴莫尼定对眼后节的潜在影响。

方法:前瞻性、安慰剂对照干预性临床试验,包括32例32眼正常个体。第1d,受试者接受一滴无防腐剂人工泪液作为安慰剂;第2d,接受一滴0.15%酒石酸溴莫尼定。收集每次用药前及用药后1、3和5h,眼压,眼灌注压(OPP)以及EDI-SD-OCT数据。

结果:相较于最初测量结果,局部应用0.15%酒石酸溴莫尼定后,在下凹($P=0.001$),颞凹1500 μm 处($P=0.003$),鼻凹1500 μm 处($P=0.003$)测得脉络膜厚度显著增加。整个研究过程中,安慰剂组脉络膜厚度未发生变化($P>0.05$)。分别使用安慰剂和溴莫尼定后眼灌注压没有显著降低($P>0.05$)。研究中未观察到不良反应。

结论:与预期相悖,局部应用0.15%酒石酸溴莫尼定导致下凹、颞凹、鼻凹处脉络膜厚度增加。这一结论可能与脉络膜血管自动调节机制有关。

关键词:溴莫尼定;脉络膜厚度;增强深度成像;眼压;光学相干断层扫描

引用: Demircan S, Gökçen G, Atas M, Gülhan A, Başkan B, Zararsiz G. 单剂量0.15%酒石酸溴莫尼定对正常个体脉络膜厚度的影响. 国际眼科杂志 2017;17(11):2000-2004

Abstract

• **AIM:** To evaluate the potential posterior segment effects of topical application of brimonidine - purite 0.15% through measurement of choroidal thickness (CT) in healthy eyes using enhanced depth imaging spectral - domain optical coherence tomography (EDI-SD-OCT).

• **METHODS:** Thirty-two eyes of 32 healthy subjects were included in this prospective, placebo - controlled interventional clinical trial. They received one drop of topical preservative-free artificial tears as placebo for the first day and one drop of brimonidine - purite 0.15% for the second day. Intraocular pressure, ocular perfusion pressure (OPP), and EDI-SD-OCT were performed at baseline, at 1, 3 and 5h after the treatments.

• **RESULTS:** Compared to the measurements obtained at baseline, the CT measurements obtained after the topical application of brimonidine - purite 0.15% significantly increased at the sub-fovea ($P=0.001$), at temporal 1500 μm to the fovea ($P=0.003$) and at nasal 1500 μm to the fovea ($P=0.003$). Choroidal thickness was unchanged in placebo group during the study ($P>0.05$). There was no significant reduction in the OPP in both groups ($P>0.05$). There were no adverse events during the study.

• **CONCLUSIONS:** Contrary to expectations, topical administration of brimonidine-purite 0.15% resulted with thickening of sub-foveal, temporal and nasal CT. This might be related to altered auto-regulation mechanisms in choroidal vessels.

• **KEYWORDS:** brimonidine; choroidal thickness; enhanced depth imaging; intraocular pressure; optical coherence tomography

DOI:10.3980/j.issn.1672-5123.2017.11.03

Citation: Demircan S, Gökçen G, Atas M, Gülhan A, Başkan B, Zararsiz G. The effect of single dose of brimonidine-purite 0.15% on choroidal thickness in healthy volunteers. *Guoji Yanke Zazhi (Int Eye Sci)* 2017;17(11):2000-2004

INTRODUCTION

Brimonidine, which is a selective α -2 adrenergic agonist, effectively decrease intraocular pressure (IOP) via reduced aqueous humor production and expanded uveoscleral outflow^[1-2]. Today, this is widely used as a topical anti-glaucoma drug as monotherapy, adjunctive therapy or replacement therapy for long-term treatment of glaucoma^[3-6]. Brimonidine demonstrated good ocular distribution after topical application in experimental pharmacokinetic studies^[7]. On topical application, brimonidine-purite easily penetrates the cornea and reduces the IOP within 1h. Peak concentration is

reached within 2 to 3h and the IOP lowering effect continues 10 to 14h after instillation^[3,6].

Brimonidine may be attractive due to its additional neuro-protective properties. Anterior segment vasoconstriction has been noted with topical brimonidine, presumably mediated *via* local extra-junctional $\alpha 2$ -adrenergic receptors^[8-9]. However, there is a little knowledge about the potential vasoconstrictor effects of brimonidine through the posterior pole of the eyeball. Significant concentrations of brimonidine were found to activate $\alpha 2$ -adrenergic receptors selectively in the posterior segments of the eye ball^[10-11]. These vasoconstrictor effects have clinical significance due to the prelaminar structures of the optic nerve receives the blood supply from the peripapillary choroidal vessels^[12]. A reduced choroidal perfusion in the prelaminar optic nerve may a part of the pathophysiologic characteristics of glaucomatous optic neuropathy^[13].

In light of the improvements in imaging modalities, our knowledge about the choroid has been advancing and choroidal changing in various diseases has been giving growing awareness. Such proceedings may act an important role about the knowledge of the pathophysiology of many retinopathies and can make guide therapeutic options easier. The use of enhanced depth imaging spectral-domain optical coherence tomography (EDI-SD-OCT) has enabled better assessment of posterior ocular anatomy and has been shown to detect changes in choroidal thickness (CT) non-invasively.

We designed this study to evaluate the potential vasoconstrictor effects of topical application of brimonidine-purite 0.15% through posterior segment of the eyeball by measuring CT in healthy subjects using EDI-SD-OCT.

SUBJECTS AND METHODS

Study Population and Design This prospective, placebo controlled interventional study was conducted at the Kayseri Training and Research Hospital between May and October 2015. Thirty-two eyes of 32 healthy volunteers were recruited. The study protocol was approved by the Institutional Ethical Review Board and performed according to the Declaration of Helsinki. Written informed consent to participate in the study was obtained from each subject. Assessments were performed in only one eye (right) of each subject. After baseline measurements, all subjects received preservative-free artificial tears (one drop for each eye) as the placebo group for the first day of the study. One, three and five hours later, all measurements were repeated. For the second day of the study, after baseline measurements, brimonidine-purite 0.15% (alphagan-P 0.15%, Allergan Pharmaceuticals Ltd., Westport, Ireland) was administered to the same eyes (one drop for each eye). One, three and five hours later, all measurements were repeated. Baseline measurements were taken at 08:00 am to 09:00 am for minimizing the diurnal variations.

Examination Protocol and Study Measurements A detailed medical history with complete physical and ophthalmic examination including, best corrected visual acuity (BCVA) with Snellen chart or logarithm of the minimum angle resolution (logMAR) equivalent, refraction, slit-lamp

biomicroscopy, IOP, gonioscopy and funduscopy examination using a 90-diopter lens were performed as pre-study screening.

Inclusion Criteria Inclusion criteria were defined as normal ophthalmic findings, refractive errors of less than 3D and an IOP less than 21 mmHg measured using Goldmann tonometry. A normal optic disc was defined as cup/disc area ratio less than 0.5, a neuro-retinal rim with no glaucomatous changes such as localized rim defects or peripapillary atrophy.

Exclusion Criteria Exclusion criteria were defined as history of previous ocular trauma or surgery, presence of cataract, glaucoma, strabismus, eccentric fixation, laser treatment, retinal or optic nerve disorders, smoking or pregnancy.

Systemic Hemodynamics An automated oscillometric device was used to measure systolic, diastolic and mean arterial blood pressures (SBP, DBP and MAP, respectively) on the upper arm.

Measurement of IOP A Goldmann tonometer (AT900; Haag-Streit, K oniz, Switzerland) was used to measure IOP after one drop of fluorescein with Proparacaine-HCl.

Ocular Perfusion Pressure The 2/3 MAP - IOP formulation, which is based on the evidence that the pressure in choroidal veins is almost equal to the IOP, used for the calculation of ocular perfusion pressure^[14-16].

OCT Imaging The CT was measured by EDI-SD-OCT. Each section, consisting of 30 average scans, was obtained in a 15 x 30 degree rectangle centered at the macula. The horizontal section passing directly through the center of the fovea was selected. The resulting images were viewed and measured using the Heidelberg software (Version 5.6.4.0; Spectralis OCT Heidelberg Engineering, Dossenheim, Germany) (Figure 1).

Choroidal thickness was determined as the distance from the outer surface of the hyper-reflective line, referred to as the "retinal pigment epithelium" layer, to the hyper-reflective line of the inner scleral border. Choroidal thickness was measured at the fovea, 1500 μ m nasal and 1500 μ m temporal to the fovea in a horizontal section. The axial resolution was 3.9 mm digital, which is the same as routine OCT images obtained by Spectralis OCT. Measurements were evaluated by two independent ophthalmologists (Demircan S, Ataş M), and the mean value was generated for analysis. The measurements were performed at the same time of the day in order to avoid diurnal fluctuations. Spectralis OCT uses a signal-to-noise estimate (SNR in dB) for the quality score. After all exposures, uncentered scans or scans with SNR <7 dB were excluded from the study.

Statistical Analysis A pilot study was conducted with 10 subjects (10 eyes) and CT variables were measured. Based on the summary statistics of the obtained data, we applied power analysis with $\alpha = 0.05$ and $\beta = 0.20$ (power = 0.80). The minimum sample size was calculated as 31 eyes. Thus, we collected the data of 32 patients (32 eyes). Power analyses were performed using PASS 11.0 (Power analysis statistical system) software. Shapiro-Wilk's test was applied

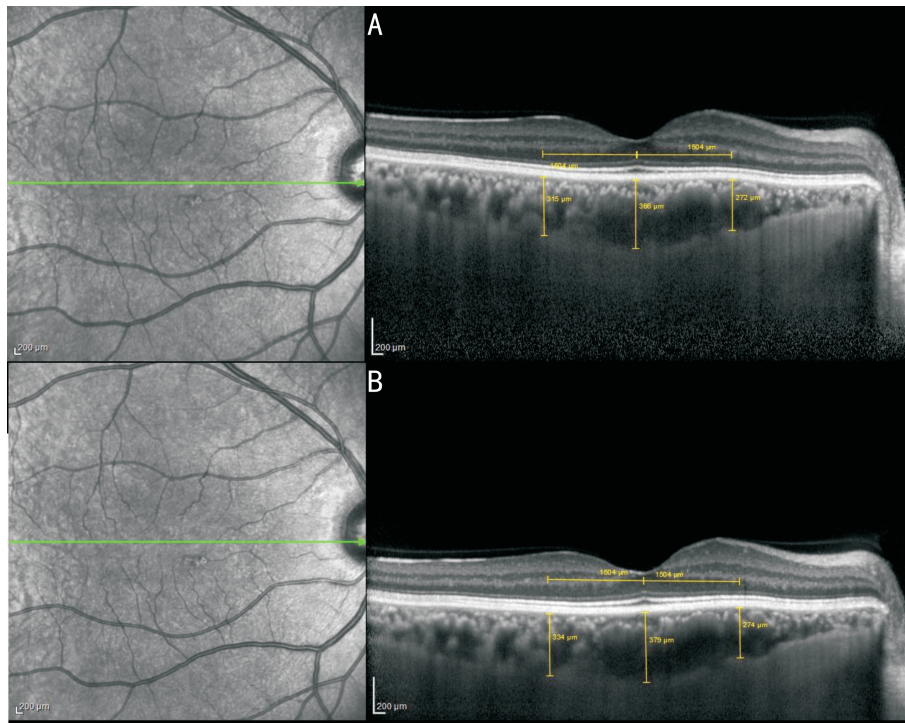


Figure 1 Choroidal thickness was measured at the sub-fovea, 1500 μm nasal and 1500 μm temporal to the fovea in a horizontal section using enhanced depth imaging in spectral domain optical coherence tomography A: Baseline measurements; B: Measurements at 2h after the application of brimonidine-purite 0.15%.

Table 1 Comparison of brimonidine and placebo groups of choroid thickness over time

Variable	Time (h)				P
	Baseline	1	3	5	
Nasal choroid thickness (μm)					
Placebo	326.94±131.80	327.44±132.45	324.56±124.13	321.00±136.12	0.246
Brimonidine	326.00±130.41	351.25±143.20	346.00±146.01	337.13±132.66	0.003
P	0.417	0.006	0.046	0.007	
Central choroid thickness (μm)					
Placebo	381.06±131.22	381.81±131.30	374.06±118.06	371.25±127.14	0.139
Brimonidine	381.75±131.48	410.25±142.06	400.63±137.97	401.81±140.95	0.001
P	0.462	0.003	0.012	0.001	
Temporal choroid thickness (μm)					
Placebo	361.38±116.96	363.56±116.41	359.25±99.56	360.75±99.74	0.327
Brimonidine	362.63±114.41	393.63±130.23	382.63±109.64	383.75±103.79	0.003
P	0.391	<0.001	0.024	<0.001	
OPP (mmHg)					
Placebo	43.49±4.45	43.31±5.14	40.78±6.54	42.21±3.88	0.267
Brimonidine	43.32±4.41	41.65±7.28	43.26±6.75	43.57±5.90	0.420
P	0.203	0.346	0.248	0.387	
IOP (mmHg Appl.)					
Placebo	13.13±2.13	13.19±2.10	13.75±2.11	12.88±1.67	0.053
Brimonidine	13.25±1.98	12.19±2.20	10.94±1.39	11.13±1.78	<0.001
P	0.164	0.048	<0.001	0.001	

Values are expressed as mean±SD; OPP; Ocular perfusion pressure; IOP; Intraocular pressure; Different superscripts in a row indicate a statistical significant difference among measures.

histogram and q-q plots were examined to assess the data normality. To compare the differences between groups, a two-sided paired t-test or one-way repeated measures analysis of variance were applied. Bonferroni test was used for multiple comparisons. Analyses were applied using R 3.2.2. (www.r-project.org). P value less than 5% was considered as

statistically significant.

RESULTS

Thirty two eyes of 32 subjects (18 male, 14 female) were investigated. The mean age of the subjects was 34.10±6.43 (range 26-42y). All eyes had a BCVA of 20/20 or its logMAR equivalent. In the study eyes, compared to the

measurements obtained at baseline, the CT measurements obtained after the topical application of brimonidine – purite 0.15% significantly increased at the sub-fovea, at temporal 1500 μm to the fovea and at nasal 1500 μm to the fovea (Table 1).

At the sub-fovea, the CT measured at baseline was $381.75 \pm 131.48 \mu\text{m}$ which increased to $410.25 \pm 142.06 \mu\text{m}$ at 1h, $400.63 \pm 137.97 \mu\text{m}$ at 3h and $401.81 \pm 140.95 \mu\text{m}$ at 5h after the application of brimonidine – purite 0.15% ($P = 0.001$).

At the nasal part, the CT measured at baseline was $326.00 \pm 130.41 \mu\text{m}$ which increased to $351.25 \pm 143.20 \mu\text{m}$ at 1h, $346.00 \pm 146.01 \mu\text{m}$ at 3h and $337.13 \pm 132.66 \mu\text{m}$ at 5h after the application of brimonidine – purite 0.15% ($P = 0.003$).

At the temporal part, the CT measured at baseline was $362.63 \pm 114.41 \mu\text{m}$ which increased to $393.63 \pm 130.23 \mu\text{m}$ at 1h, $382.63 \pm 109.64 \mu\text{m}$ at 3h and $383.75 \pm 103.79 \mu\text{m}$ at 5h after the application of brimonidine – purite 0.15% ($P = 0.003$).

Choroidal Thickness was unchanged in placebo group during the study ($P > 0.05$).

The mean IOP significantly decreased from 13.25 ± 1.98 mmHg to 12.19 ± 2.20 mmHg at 1h, 10.94 ± 1.39 mmHg at 3h and 11.13 ± 1.78 mmHg at 5h after the application of brimonidine – purite 0.15% ($P < 0.001$). In placebo control eyes, the mean IOP was not changed during the study ($P > 0.05$). There were no significant reductions in the OPP in both groups ($P > 0.05$). There were no adverse events during the study. Brimonidine – purite 0.15% was well tolerated by all the participants.

DISCUSSION

In this study, EDI – SD – OCT measurement of sub-foveal, nasal and temporal CT showed that administration of brimonidine – purite 0.15% to healthy eyes resulted in significantly thicker CT than those of the baseline measurements.

Although little is known about the regulation of CT and its role in different diseases, it is well-known that CT can be altered by at least 3 mechanisms; 1) local signaling that either stimulates or inhibits the fluid pumping capacity of the RPE thereby altering the amount of fluid flux from the retina into the choroid^[17]; 2) an increase or decrease in vascular permeability of the choriocapillaris that affects the amount of protein that leaks out of these vessels, which in turn changes the oncotic pressure in the choroid^[18]; 3) dilation or constriction of both the vascular and nonvascular smooth muscles^[19].

There are both endogenous and exogenous vasoactive substances that have been shown to alter CT.

Brimonidine has complex vasoactive properties. Rosa *et al*^[20] found that brimonidine caused dose-dependent dilation of all larger retinal arterioles and mild dilation of some smaller retinal arterioles at low concentrations (≤ 10 nM). It should be noted that this vasodilatory response was evident at therapeutic concentrations of brimonidine (i. e. vitreous concentrations $< 10 - 100$ nM after topical

administration)^[10,21]. Clinical studies indicated that the effect of this complex vasoactive behavior of retinal blood flow remained unchanged with brimonidine treatment^[22–23]. We suggest that increased CT may be related to the vasoactive properties of brimonidine *via* dilation of choroidal vessels.

Brimonidine may induce vessel dilation through its interaction with the nitric oxide (NO) signaling cascade. Some studies have shown that $\alpha 2$ mediated NO release plays a role in increasing CT locally by relaxing both vascular and nonvascular smooth muscles. The beneficial effect of brimonidine in terms of vasodilation and flow enhancement may be dependent on the local concentration of brimonidine, distribution and function of $\alpha 2$, endothelial NO synthase activity, endothelin – 1 level and the local metabolic environment. There is a dense network of sympathetic innervations of the choroid that suggests a mechanism of choroidal blood flow regulation^[14,24]. Our study is the first to present evidence of the regulation of blood flow in the choroidal circulation *in vivo*, as measured by thickness measurements using SD – OCT. In addition, this investigation demonstrated significant change in the thickness of the choroid, despite no significant change in OPP. Thus, these results suggest some type of blood flow regulation in the choroid. The mechanism of this regulation is probably mediated by the intricate sympathetic innervations or auto-regulation in the choroidal vessels^[14]. The effect of brimonidine on CT is interesting because altered auto-regulation appears to be a contributing factor in the pathophysiology of glaucoma^[18,24]. On the other hand, Weigert *et al*^[25] reported that topical administration of brimonidine showed a decrease in choroidal blood flow, most probably due to a direct vasoconstrictor effect. Because brimonidine decreased the IOP under baseline conditions, it is unlikely that the reduction in blood flow is caused by an indirect effect on perfusion pressure. Their results are compatible with previous findings in animal models showing pronounced vasoconstrictor effects of brimonidine in the rabbit ciliary body with *in vitro* data showing vasoconstrictor effects in isolated porcine ciliary arteries^[16,19].

When investigating the effects of a topical anti-glaucoma drug on ocular blood flow in the posterior pole of the eye *in vivo*, one has to consider that a decrease in the IOP may lead to a concomitant increase in the OPP making any blood flow data difficult to interpret. Based on the data in the literature, the effects of brimonidine on arterial BP are controversial. Quaranta *et al*^[26] found that brimonidine 0.2% induces a statistically significant reduction of the SBP and DBP on the 24 – hour BP profile. In a short – term randomized clinical trial, Derick *et al*^[27] showed that brimonidine 0.2% induces a statistically significant change in mean SBP at 1, 2, 6, and 8h after its most recent instillation and 21d after the beginning of the treatment. The mean changes in diurnal DBP were significantly different from baseline. In addition, Stewart *et al*^[28] found a significant reduction in BP after administration of brimonidine alone or in association with timolol. Other randomized clinical studies on brimonidine showed that long-term results did not express any significant reduction in the

SBP and DBP^[3-6]. Our study demonstrated that brimonidine was not able to affect the OPP significantly compared to baseline.

A limitation of this study is that brimonidine could have undergone systemic absorption by the nasolacrimal pathway. However, Acheampong *et al*^[21] found that experiments with unilateral topical dosing showed high drug levels in the treated eye compared to the contralateral untreated eye and plasma, suggesting that brimonidine penetrates into the posterior tissues by a local route instead of systemic absorption. Systemic absorption of topical brimonidine may occur, peak plasma concentrations occurring within 1–4h with a half-life of approximately 2.5h after administration^[29]. In addition the study design as such addresses the very short term effects of brimonidine on the ocular circulation, the effect of a single dose in other words. This does not reflect on the real situation of chronic use of brimonidine by glaucoma and ocular hypertension patients.

In conclusion, we found that CT significantly increased in healthy subjects after the topical application of brimonidine-purite 0.15% drops into the eye when compared to baseline levels. This result also suggests that topical brimonidine-purite 0.15% would reach beyond the retina in sufficient concentrations for biological activity such as vasodilatory response at choroidal levels. As our study is a preliminary report, further larger studies are needed to provide further insights into the complex vasoactive properties of brimonidine.

REFERENCES

- 1 Fan S, Agrawal A, Gulati V, Neely DG, Toris CB. Daytime and nighttime effects of brimonidine on IOP and aqueous humor dynamics in participants with ocular hypertension. *J Glaucoma* 2014;23(5):276–281
- 2 Aung T, Sharma S, Trikha S, Perera S. Clinical effectiveness of brinzolamide 1% – brimonidine 0.2% fixed combination for primary open-angle glaucoma and ocular hypertension. *Clin Ophthalmol* 2015; 24;9:2201–7
- 3 Greig SL, Deeks ED. Brinzolamide/brimonidine: a review of its use in patients with open-angle glaucoma or ocular hypertension. *Drugs Aging* 2015;32(3):251–260
- 4 Aihara M, Adachi M, Hamada N, Honda N, Koseki N, Matsuo H, Miyata K, Otani S, Unoki K. Effects of switching from timolol to brimonidine in prostaglandin analog and timolol combination therapy. *J Ocul Pharmacol Ther* 2015;31(8):482–486
- 5 Feke GT, Rhee DJ, Turalba AV, Pasquale LR. Effects of dorzolamide-timolol and brimonidine-timolol on retinal vascular autoregulation and ocular perfusion pressure in primary open angle glaucoma. *J Ocul Pharmacol Ther* 2013;29(7):639–645
- 6 Katz LJ, Rauchman SH, Cottingham AJ Jr, Simmons ST, Williams JM, Schiffman RM, Hollander DA. Fixed-combination brimonidine-timolol versus latanoprost in glaucoma and ocular hypertension; a 12-week, randomized, comparison study. *Curr Med Res Opin* 2012;28(5):781–788
- 7 Katz LJ. Twelve-month evaluation of brimonidine-purite versus brimonidine in patients with glaucoma or ocular hypertension. *J Glaucoma* 2002;11(2):119–126
- 8 Guo X, Namekata K, Kimura A, Noro T, Azuchi Y, Semba K, Harada C, Yoshida H, Mitamura Y, Harada T. Brimonidine suppresses loss of retinal neurons and visual function in a murine model of optic neuritis. *Neurosci Lett* 2015;592:27–31
- 9 Mayama C, Araie M. Effects of antiglaucoma drugs on blood flow of optic nerve heads and related structures. *Jpn J Ophthalmol* 2013;57(2):133–149
- 10 Takamura Y, Tomomatsu T, Matsumura T, Takihara Y, Kozai S, Arimura S, Yokota S, Inatani M. Vitreous and aqueous concentrations of brimonidine following topical application of brimonidine tartrate 0.1%

- ophthalmic solution in humans. *J Ocul Pharmacol Ther* 2015;31(5):282–285
- 11 Shen J, Durairaj C, Lin T, Liu Y, Burke J. Ocular pharmacokinetics of intravitreally administered brimonidine and dexamethasone in animal models with and without blood – retinal barrier breakdown. *Invest Ophthalmol Vis Sci* 2014;55(2):1056–1066
- 12 Hayreh SS. Blood supply of the optic nerve head and its role in optic atrophy, glaucoma, and oedema of the optic disc. *Br J Ophthalmol* 1969;53(11):721–748
- 13 Fan N, Wang P, Tang L, Liu X. Ocular blood flow and normal tension glaucoma. *Biomed Res Int* 2015;2015:1–7
- 14 Luo X, Shen YM, Jiang MN, Lou XF, Shen Y. Ocular blood flow autoregulation mechanisms and methods. *J Ophthalmol* 2015; 2015:864871
- 15 Maepea O. Pressures in the anterior ciliary arteries, choroidal veins and choriocapillaris. *Exp Eye Res* 1992;54(5):731–736
- 16 Reitsamer HA, Kiel JW. A rabbit model to study orbital venous pressure, intraocular pressure, and ocular hemodynamics simultaneously. *Invest Ophthalmol Vis Sci* 2002;43(12):3728–3734
- 17 Ymer J, Wildsoet CF. The role of the retinal pigment epithelium in eye growth regulation and myopia; a review. *Vis Neurosci* 2005;22(3):251–261
- 18 Pendrak K, Papastergiou GI, Lin T, Laties AM, Stone RA. Choroidal vascular permeability in visually regulated eye growth. *Exp Eye Res* 2000;70(5):629–637
- 19 Kur J, Newman EA, Chan – Ling T. Cellular and physiological mechanisms underlying blood flow regulation in the retina and choroid in health and disease. *Prog Retin Eye Res* 2012;31(5):377–406
- 20 Rosa RH Jr, Hein TW, Yuan Z, Xu W, Pechal MI, Geraets RL, Newman JM, Kuo L. Brimonidine evokes heterogeneous vasomotor response of retinal arterioles; diminished nitric oxide – mediated vasodilation when size goes small. *Am J Physiol Heart Circ Physiol* 2006; 291(1):H231–H238
- 21 Acheampong AA, Shackleton M, John B, Burke J, Wheeler L, Tang-Liu D. Distribution of brimonidine into anterior and posterior tissues of monkey, rabbit, and rat eyes. *Drug Metab Dispos* 2002;30(4):421–429
- 22 Schmidt KG, Klingmuller V, Gouveia SM, Osborne NN, Pillunat LE. Short posterior ciliary artery, central retinal artery, and choroidal hemodynamics in brimonidine – treated primary open – angle glaucoma patients. *Am J Ophthalmol* 2003;136(6):1038–1048
- 23 Spada CS, Nieves AL, Burke JA, Wheeler LA, Woodward DF. Differential effects of alpha – adrenoceptor agonists on human retinal microvessel diameter. *J Ocul Pharmacol Ther* 2001;17(3):255–277
- 24 Calvo P, Ferreras A, Polo V, Güerri N, Seral P, Fuertes-Lazaro I, Pablo LE. Predictive value of retrobulbar blood flow velocities in glaucoma suspects. *Invest Ophthalmol Vis Sci* 2012;53(7):3875–3884
- 25 Weigert G, Resch H, Garhofer G, Fuchsjäger-Mayrl G, Schmetterer L. Effects of topical clonidine versus brimonidine on choroidal blood flow and intraocular pressure during squatting. *Invest Ophthalmol Vis Sci* 2007;48(9):4220–4225
- 26 Quaranta L, Gandolfo F, Turano R, Rovida F, Pizzolante T, Musig A, Gandolfo E. Effects of topical hypotensive drugs on circadian IOP, blood pressure, and calculated diastolic ocular perfusion pressure in patients with glaucoma. *Invest Ophthalmol Vis Sci* 2006; 47(7):2917–2923
- 27 Derick RJ, Robin AL, Walters TR, Barnebey HS, Choplin N, Schuman J, Kelley EP, Chen K, Stoecker JF. Brimonidine tartrate; a one-month dose response study. *Ophthalmology* 1997;104(1):131–136
- 28 Stewart WC, Stewart JA, Jackson AL. Cardiovascular effects of timolol maleate, brimonidine or brimonidine/timolol maleate in concomitant therapy. *Acta Ophthalmol Scand* 2002;80(3):277–281
- 29 Bowman RJ, Cope J, Nischal KK. Ocular and systemic side effects of brimonidine 0.2% eye drops (Alphagan) in children. *Eye (Lond)* 2004;18(1):24–26