

Recurrent retinal detachment in silicone oil-filled eyes treated with two-port 27-gauge pars plana vitrectomy

San-Mei Liu^{*}, Jie Li^{*}, Wen-Tao Dong, Fang Li, Cai-Hong Zhou, Xiao-Lan Tang, Yu-Yu Zhao, Wen-Jie Jiang, Xiao-Dan Xu, Jie Zhong

Sichuan Academy of Medical Sciences & Sichuan People's Hospital; Affiliated Hospital of University of Electronic Science and Technology of China, Chengdu 610072, Sichuan Province, China.

Co-first authors: San-Mei Liu and Jie Li.

Correspondence to: Jie Zhong. Sichuan Academy of Medical Sciences & Sichuan People's Hospital; Affiliated Hospital of University of Electronic Science and Technology of China, Chengdu 610072, Sichuan Province, China. 13808063276@163.com

Received: 2016-12-14 Accepted: 2017-06-29

双通道 27G 玻璃体切除术治疗硅油填充眼复发性视网膜脱离

刘三梅^{*}, 李杰^{*}, 董文韬, 李芳, 周采虹, 唐晓兰, 赵渝宇, 江文婕, 徐晓单, 钟捷

(作者单位:610072 中国四川省成都市,电子科技大学附属医院四川医学科学院·四川省人民医院)

^{*}:刘三梅和李杰对本文贡献一致。

作者简介:刘三梅,毕业于华西医科大学,硕士,副主任医师,研究方向:玻璃体视网膜疾病。李杰,毕业于四川大学,博士,主治医师,研究方向:玻璃体视网膜疾病,视网膜新生血管性疾病。

通讯作者:钟捷,毕业于重庆医科大学,本科,主任医师,副主任,研究方向:玻璃体视网膜疾病。13808063276@163.com

摘要

目的:研究双通道 27G 玻璃体切除术在硅油填充状态下治疗复发性视网膜脱离的可行性及优缺点。

方法:回顾性研究。7 例硅油填充眼在随访时发现下方视网膜浅脱离。在硅油填充状态下行双通道 27G 玻璃体切除术。术中完成视网膜表面增殖膜剥离、视网膜下液抽吸,并在视网膜复位后行硅油下视网膜激光光凝术,根据患眼病情辅以巩膜外垫压或环扎。

结果:术后所有患眼视网膜均成功复位,术中未发生严重并发症。所有患眼术后眼表反应轻且视力迅速恢复至术前水平。1 眼在术后 20d 出现视网膜再脱离,经传统的硅油取出联合视网膜复位术成功复位视网膜。

结论:双通道 27G 玻璃体切除术是一个治疗硅油填充眼早期视网膜再脱离的有效方法,可能具有更高的性价比。

关键词:双通道玻璃体切除术;27G;复发性视网膜脱离;硅油

引用:刘三梅,李杰,董文韬,李芳,周采虹,唐晓兰,赵渝宇,江文婕,徐晓单,钟捷. 双通道 27G 玻璃体切除术治疗硅油填充眼复发性视网膜脱离. 国际眼科杂志 2017;17(9):1620-1624

Abstract

• **AIM:** To evaluate the feasibility and advantages of two-port 27-gauge pars plana vitrectomy for treatment of recurrent retinal detachment in silicone oil dwelling eyes.

• **METHODS:** A retrospective study. Two-port 27-gauge pars plana vitrectomy was performed in 7 eyes with recurrent retinal detachment without remove of silicone oil. Proliferative membrane peeling, endolaser treatment, and drainage of subretinal fluid were performed. Scleral bulking was performed if necessary.

• **RESULTS:** Successful retina re-attachment was accomplished in all eyes. No visually significant intraoperative complication occurred. All eyes experienced quick recovery of visual acuity and mild postoperative irritation. One eye developed a recurrent inferior retinal detachment in 20d after the surgery using non-remove technique, and recovered after conventional silicone oil removal and retinal reattachment surgery.

• **CONCLUSION:** Two-port 27-gauge pars plana vitrectomy is an efficacious (and potentially cost-efficient) method to treat early stage recurrent retinal detachment in silicone oil dwelling eyes.

• **KEYWORDS:** two-port pars plana vitrectomy; 27-gauge; recurrent retinal detachment; silicone oil.

DOI:10.3980/j.issn.1672-5123.2017.9.04

Citation: Liu SM, Li J, Dong WT, Li F, Zhou CH, Tang XL, Zhao YY, Jiang WJ, Xu XD, Zhong J. Recurrent retinal detachment in silicone oil-filled eyes treated with two-port 27-gauge pars plana vitrectomy. *Guoji Yanke Zazhi(Int Eye Sci)* 2017; 17(9):1620-1624

INTRODUCTION

Despite the improvement of pars plana vitrectomy (PPV) for decades combined with the using of silicone oil (SO) in vitreoretinal surgery, recurrent retinal detachment (RD) may still occur secondary to retinal breaks with or without proliferative retinopathy in SO filled eyes^[1-3]. Most of the recurrent RD located in the inferior quadrants^[4-5]. Surgeons commonly remove pre-existing SO followed by excessive vitreoretinal manipulation may including membrane peeling, retinotomy, retinectomy, drainage of sub-retinal fluid, endolaser and re-inject SO^[6]. Scleral buckling has also been widely used in recurrent RD treatment^[4]. Recently, simplified procedure such as conducting vitreoretinal operation without SO remove has been reported, especially after the

popularization of micro – incision vitreoretinal surgery (MIVS)^[7-11]. However, a current literature review failed to disclose any series of recurrent RD with SO filled eye treated with 27-gauge PPV using non-remove SO strategy. Here, we reported a retrospective study on 7 cases of inferior recurrent RD treated with two ports 27-gauge vitrectomy without SO remove. The surgical indications, techniques, anatomic and visual outcome were documented and analyzed in our study.

SUBJECTS AND METHODS

Patients This was a retrospective study. Seven eyes of 7 patients had been included in this study. All surgeries were performed by the same surgeon (Zhong J) between Feb. 2016 and Jun. 2016 at Sichuan Provincial People's Hospital. All eyes were diagnosed with recurrent retinal detachment (RD) using silicone oil (SO) as endotamponade 1 to 6mo after the initial vitrectomy surgery. Six eyes were initially diagnosed with rhegmatogenous retinal detachment (RRD) and one eye with tractional retinal detachment (TRD) due to proliferative diabetic retinopathy. One eye previously underwent two pars plana vitrectomy (PPV) treatments. All cases showed recurrent RD in the inferior quadrants without macular involvement. All cases of retina re-detachment were caused by one or more retinal breaks with localized pre-retinal proliferative retinopathy. Most of the retinal breaks located below the oil – fluid interface. The patients' characteristics were presented in Table 1, Figure 1A.

Surgical Techniques We performed all operations using 27-gauge Constellation Vision System (Alcon Laboratories Inc, TX, USA) and S88/OPMI Lumera T operation microscope with the RESIGHT wide-angle view system (Carl Zeiss Meditec AG, Germany).

After retrobulbar anesthesia was induced with 2% lidocaine and conjunctival disinfected with povidone-iodine, two valve-cannulas were initially placed superotemporal and superonasal at a position 3.5mm posterior to limbus after sclerotomies created by two-step insertion technique. However, no third port or infusion line were placed. The valved cannulas was helpful to avoid leakage of SO during sclerotomy creation and extraction of micro-surgery instrument.

Firstly, the 27-gauge light pipe was inserted into vitreous cavity to get a full view of fundus helped by vitrectomy cutter inposition. Then, endoillumination with scleral indentation helped to carefully exam and identify peripheral retinal pathological feature especially the retinal breaks and proliferative vitreoretinopathy (PVR) in inferior quadrants. All new formed pre-retinal PVR membranes adjacent to retinal breaks were removed by micro-cutter or end-grasping forceps (Figure 1C). The pre-retinal PVR membrane was believed be an important factor to contribute to the recurrent RD. Mild retinotomy was performed when retinal breaks edge remained curly. Then, internal sub-retinal fluid drainage was performed slowly via micro vitrector. Subsequently, all retinal

breaks were sealed by endophotocoagulation with scleral depression (Figure 1D).

Scleral buckling, bulking reinforcement or silicon sponge placement were performed in three eyes respectively. Scleral bulking was performed when anterior PVR could not be completely released and the retinal breaks were scattered inferiorly. No additional SO infusion was routinely used.

After all micro – instruments were simply removed, the sclerotomies were self – sealed without sutures. Topical antibiotic ointment was applied and the eyes were patched and shielded. Patients were strict instructed to comply to a prone positioning for 1wk.

RESULTS

Fundus visualization was adequate, and all cases achieved well retina re-attachment the 1st day after surgery. A retrospective analysis of case logs revealed operation time ranging from 20–55 (34.3±15.9min), which included the time for scleral buckling or silicon sponge placement. Postoperative best corrected visual acuity (BCVA) recovered quickly in the first few days after surgery and restored comparably to that of pre-operation and remained stable in follow up. All patients showed only mild conjunctival infection and transient postoperative aqueous inflammation. No transient low IOP, ocular hypertension or other complication was observed.

DISCUSSION

Scleral buckling and re-vitrectomy with silicone oil remove are two major conventional treatments to recurrent inferior retinal detachment in silicone oil tamponade eyes^[4-6]. Meanwhile, two – port pars plana vitrectomy reoperation without silicone oil remove has also been described in combination with or without scleral buckle for inferior retinal detachment in previous studies^[7-8,10-12].

In our study, we used the recently developed 27-gauge PPV to re-operate on seven SO tamponade eyes with recurrent inferior RD^[13-14]. We experienced most of the same advantages as other author reported. First for most, without SO remove, the operation time were considerably reduced to average 34.3min. If the time used for scleral buckling or silicon sponge placement were excluded, the operation time in all cases were less than half an hour, which may potentially significantly less than that of conventional remove – and – replace procedures. Secondly, there was no fog emerged on the posterior capsular of lens, which provide a good visualization of fundus intraoperatively. Thirdly, the interfacial tension produced by SO would hold the retina in place or reduce movement of retina^[15], which was helpful for proliferative membrane peeling, retinotomy, retinectomy, sub-retinal fluid drainage and photocoagulation. Theoretically, the less time that retina detached from the RPE, the more visional function could be preserved. With the SO holding retina in place would benefit visual function postoperatively. In our cases, BCVA of all eyes restored quickly and were comparably to that of pre-operation in 1wk.

Table 1 Clinical data of the 7 cases of recurrent retinal re-detachment underwent 2-port 27 gauge pars plana vitrectomy with silicone oil remove.

Case	Age	Sex	First diagnosis	Previous operations	Duration prior to RD (mo)	Duration of RD	Preop BCVA	Lens status	Preop retina condition	Additional operation procedures	operation time(min)	Postop BCVA (1d)	Postop IOP(1wk)	Postop BCVA (1wk)	Postop IOP(1wk)	Postop retina condition	F/U period (wk)	Last visit BCVA	Last visit IOP
1	53	F	RRD,CD	PPV,SO	6	2wk	0.25	Phakic	RD×3Q; 3 retinal breaks at 11 O'clock	ERM removal	20	0.05	16	0.2	12	Well attached	8	0.25	18
2	51	F	RRD,CD	PPV,SB,SO	4	10d	0.02	Phakic	RD×2Q; 1 retinal break at 6 O'clock	ERM removal;scleral buckle reinforcement	40	CF/80cm	15	0.02	16	Well attached	16	0.02	17
3	80	M	RRD	PPV,SSP,SO	3	2wk	0.04	Pseudophakic	RD×2Q; 1 retinal break at 7 O'clock	ERM removal	20	0.04	17	0.04	14	Well attached	16	0.04	15
4	76	M	RRD	PPV,SO	1	3d	0.15	Phakic	RD×2Q; 1 retinal break at 7 O'clock	ERM removal; silicon sponge placed	55	0.04	11	0.2	17	Well attached	16	0.25	10.1
5	66	F	RRD	PPV,SO	5	1wk	0.03	Phakic	RD×2Q; 2 retinal breaks at 3 O'clock	ERM removal	30	CF/40cm	14	0.02	12	recurrent RD×2Q at 20d postop(attached after further op)	8	0.03	14.7
6	59	F	RRD,CD	PPV×II,SB,SO	6	2wk	0.03	Aphakic	RD×2Q; 3 retinal breaks at 7 O'clock	ERM removal	20	0.03	15	0.03	13	Well attached	12	0.03	12
7	45	M	RRD,DR	PPV,SO	4	1wk	CF	Phakic	RD×2Q; 1 retinal break at 6 O'clock	ERM removal,SB	55	CF	25.6	CF	17.7	Well attached	8	CF	15

BCVA: Best corrected visual acuity; CF: Counting finger; ERM: Epiretinal membrane; F: Female; F/U: Follow-up; HM: Hand motion; LP: Light perception; M: Male; PPV: Pars plana vitrectomy; PVR: Proliferative vitreoretinopathy; Q: Quadrant; RRD: Rhegmatogenous retinal detachment; TRD: Tractional retinal detachment; SB: Scleral buckling; SO: Silicone oil injection into vitreous cavity; SSP: Silicon sponge placed; OP: Operation; CD: Choroidal detachment; DR: Diabetic retinopathy; PPV×II: Eye underwent two PPV surgery previously.

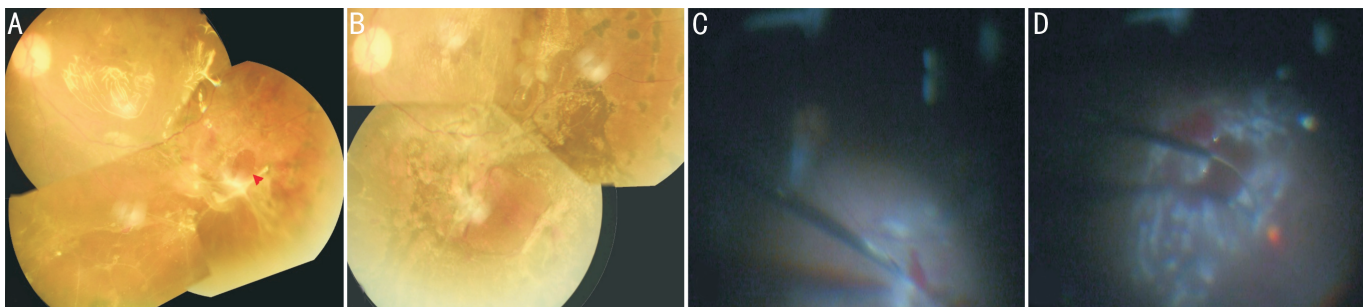


Figure 1 Fundus images and photos during operations A: Preoperative fundus image show recurrent inferior retinal detachment with ring-shape retinal hole and adjacent pre-retinal proliferation in silicone oil-filled eye of a diabetic retinopathy case; B: Inferior retina became well reattached and retina hemorrhage was absorbed completely 2mo postoperatively using a non-remove technique; C: Proliferative pre-retinal membrane was peeling off during surgery; D: Retinal laser photocoagulation was performed around the retinal break.

Here in our study, we firstly described the using of tow-port 27-gauge PPV to treat recurrent RD under dwelling silicone oil. Unlike the previous studies, we didn't use infusion line connected to air pump or endoilluminator/irrigation probe to sustain the intraocular pressure intraoperatively^[7-8,10-11]. The 27-gauge UltraVit probe system (Alcon Laboratories Inc. Fort Worth, Tex., USA) provide a valved-cannula which could keep the silicone oil from leaking though the non-valved cannula used in previous 23- or 25-gauge system. This advantage may help maintaining the intraocular pressure intraoperatively and could reduce the likelihood of infusion of SO to restore IOP in the end of surgery.

In this present study, no additional silicone oil infusion was conducted. The IOP was in a low-to-normal range right after the surgery since the remove of sub-retinal fluid. No transient low IOP (≤ 6 mmHg) observed postoperatively. Normally, there would be a dramatic decrease of IOP after removal of sub-retinal fluid. However, at the beginning of using the non-remove technique, we only chose the patient who had very shallow retinal re-detachment. So after remove of very small amount of sub-retinal fluid, we did not encounter very low IOP need reinjection of SO. In addition, two cases under went scleral buckle reinforcement and one case underwent silicone sponge placement. IOP was even in a normal-to-high range in these 3 cases at the end of surgery.

Meanwhile, there was no intraoperative complication observed and no case required conversion to 23 or 25-gauge instrument, which means that 27-gauge PPV is applicable in dealing with the complex situation like recurrent RD. When compared to 25-gauge PPV, 27-gauge instrument creates a smaller sclerotomy wound. Smaller wound is better for wound healing and reduced risk of endophthalmitis, which was supported by many previous researches^[16-18]. No sclerotomy site has been sutured at the conclusion of surgery. This non-SO-remove technique could also handle complicate case such as recurrent tractional retinal detachment in patient with proliferative diabetic retinopathy. Fundus image showed a well re-attached retina and completely absorption of sub-retinal fluid and hemorrhage (Figure 1B) 2mo after surgery.

All eyes showed a mild irritation and nonspecific inflammation in anterior segment the day after surgery and quick recovery to

a sustainable BCVA in follow up. We think the quick recovery of BCVA mainly rely on two reasons; 1) all cases were in early stage of recurrent RD (less than 2wk) with macular unaffected; 2) simplified operation procedure reduced both operation time and surgical stress response induced by invasive procedures. Without remove and reinfusion of silicone oil, we did not only reduce surgical time but also save silicon oil. Thus, this is a potential cost-efficient surgical technique compared to the conventional remove-and-replace technique. Although all case had a successful anatomic re-attachment after surgery, however, one eye developed recurrent inferior RD in 20d after the surgery. The recurrence of sub-retinal fluid may be derived from some undetected retinal tears which fell to be photocoagulated.

Our present study remains limited by small sample size, and most of them are relatively easy cases without multiple retinal surgery history or severe PVR. Furthermore, the long-term prognosis need further follow-up. Meanwhile, we don't have remove-and-replace group serve as control. However, these limits cannot deny that two-port 27-gauge PPV under SO is an efficacious and potentially cost-efficient method for recurrent RD treatment. Valved 27-gauge PPV system introduced less invasive procedure and possible more stable IOP compared to previous non-valved cannula in 23G or 25G PPV system. Thus, two-port 27-gauge PPV would be a considerable choice for recurrent RD without severe PVR in silicone oil filled eyes.

REFERENCES

- 1 Cox MS, Trese MT, Murphy PL. Silicone oil for advanced proliferative vitreoretinopathy. *Ophthalmology* 1986;93(5):646-650
- 2 McCuen BW, Landers MB, Machemer R, Petersen MR. The use of silicone oil following failed vitrectomy for retinal detachment with advanced proliferative vitreoretinopathy. *Ophthalmology* 1985;92(8):1029-1034
- 3 Riemann CD, Miller DM, Foster RE. Outcomes of transconjunctival sutureless 25-gauge vitrectomy with silicone oil infusion. *Retina* 2007;27(3):296-303
- 4 Wei Y, Wu G, Xu K, Wang J, Zu Z, Wang R. The outcomes of scleral buckling versus re-vitrectomy for the treatment of recurrent inferior retinal detachment in silicone oil tamponade eyes. *Acta Ophthalmologica* 2016;94(7):e624-e628
- 5 Sharma T, Gopal L, Shanmugam MP, Bhende PS, Agrawal R,

Badrinath SS, Samanta TK,. Management of recurrent retinal detachment in silicone oil-filled eyes. *Retina* 2002;22(2):153-157

6 Vilaplana Blanch D, Escoto Gonzalez R, Guinot Saera A. Treatment of retinal re-detachment in eyes with intraocular silicone oil. *Archivos de la Sociedad Espanola de Oftalmologia* 2001;76(4):241-248

7 Sigler EJ, Randolph JC, Calzada JI, Charles S. Anatomical and visual outcomes after two-port pars plana vitrectomy reoperation under silicone oil for epimacular membrane or recurrent retinal detachment. *Retina* 2014;34(10):1939-1344

8 Charles S, Randolph JC, Sigler EJ. Pars plana vitrectomy reoperation without removing silicone oil. *Retina* 2012;32(8):1664-1665

9 Acar MA, Unlu N, Hazirolan D, Demir MN, Uney GO, Ornek F. Conventional surgery for complicated retinal detachment in silicone oil-filled eyes. *Eur J Ophthalmol* 2011;21(3):290-295

10 Yang CM, Hsieh YT, Yang CH, Liu KR. Irrigation-free vitreoretinal surgery for recurrent retinal detachment in silicone oil-filled eyes. *Eye* 2006;20(12):1379-1382

11 Colucciello M. Two-port pars plana vitrectomy surgery: a prospective interventional case series. *Eye* 2005;19(8):869-872

12 Sigler EJ, Randolph JC, Calzada JI. Traction retinal detachment under silicone oil treated with two-port, 25-gauge pars plana vitrectomy and scissor segmentation in a child with familial exudative vitreoretinopathy. *Retin Cases Brief Rep* 2013;7(3):183-187

13 Osawa S, Oshima Y. 27 - Gauge vitrectomy. *Developments in Ophthalmology* 2014;54:54-62

14 Oshima Y, Wakabayashi T, Sato T, Ohji M, Tano Y. A 27-gauge instrument system for transconjunctival sutureless microincision vitrectomy surgery. *Ophthalmology* 2010;117(1):93-102 e2

15 de Juan E, Jr. , McCuen B, Tiedeman J. Intraocular tamponade and surface tension. *Surv Ophthalmol* 1985;30(1):47-51

16 Scott IU, Flynn HW, Dev S, Shaikh S, Mittra RA, Arevalo JF, Kychenthal A, and Acar A. Endophthalmitis after 25-gauge and 20-gauge pars plana vitrectomy: incidence and outcomes. *Retina* (Philadelphia, Pa) 2008;28(1):138-142

17 Bamonte G, Mura M, Stevie Tan H. Hypotony after 25 - gauge vitrectomy. *Am J Ophthalmol* 2011;151(1):156-160

18 Kunimoto DY, Kaiser RS. Incidence of endophthalmitis after 20- and 25-gauge vitrectomy. *Ophthalmology* 2007;114(12):2133-2137