

Glaucomatous changes in macular ganglion cell detected by spectral domain optical coherence tomography: comparison with peripapillary retinal nerve fiber layer

Asaad A. Ghanem, Dalia Sabry, Rania Kamel, Ayman Abd El-Ghafar

Mansoura Ophthalmic Center, Mansoura University, Mansoura 35516, Egypt

Correspondence to: Asaad A. Ghanem. Mansoura Ophthalmic Center, Mansoura University, Mansoura 35516, Egypt. asaadghanem@hotmail.com

Received: 2015-02-19 Accepted: 2015-12-28

比较应用 SD-OCT 检测青光眼患者黄斑区节细胞与视盘周围视网膜神经纤维层的改变

Asaad A. Ghanem, Dalia Sabry, Rania Kamel, Ayman Abd El-Ghafar

(作者单位:埃及,曼苏拉 35516,曼苏拉大学,曼苏拉眼科中心)

通讯作者:Asaad A. Ghanem. asaadghanem@hotmail.com

摘要

目的:通过节细胞内网状层(GCIPL)评估中度和重度青光眼的损伤程度并比较其与视盘周围视网膜神经纤维层(PRNFL)的诊断效能,包括敏感性与特异性及 ROC 曲线下面积(AUC)。

方法:前瞻性研究。共 210 眼(包括中度青光眼患者 30 例 54 眼,重度青光眼患者 34 例 59 眼和正常人 50 例 97 眼)纳入本研究。所有参与者均接受全面眼科检查,包括视野检查、3D-OCT 视盘检查和 3D-OCT 黄斑部垂直扫描。记录并比较所有参与者的 GCIPL 和 PRNFL 的 AUC、敏感性与特异性。

结果:在中度和重度青光眼组中,上部、下部及整体 GCIPL 和 PRNFL 厚度明显变薄($P < 0.001$)。在中度青光眼组中,GCIPL 的敏感度与特异性高于 PRNFL(仅上半部分敏感性相同)。重度青光眼组,上部、下部及整体 GCIPL 的敏感度均低于 PRNFL。整体 GCIPL 的特异性低于 PRNFL。上部 GCIPL 的特异性高于 PRNFL。下部 GCIPL 的特异性与 PRNFL 相同。

结论:对于区分中度和重度青光眼,黄斑 GCIPL 参数的功能远高于 PRNFL。两者联合在病情分析中效果最优,能够提供更准确的损伤程度评估。

关键词:中度青光眼;重度青光眼;节细胞层;节细胞内网状层;视盘周围视网膜神经纤维层

引用:Asaad A. Ghanem, Dalia Sabry, Rania Kamel, Ayman Abd El-Ghafar. 比较应用 SD-OCT 检测青光眼患者黄斑区节细胞与视盘周围视网膜神经纤维层的改变. 国际眼科杂志 2016; 16(3):409-415

Abstract

• **AIM:** To evaluate the extent of damage caused by moderate and severe glaucoma on ganglion cell inner plexiform layer (GCIPL) and to evaluate the diagnostic performance of this layer compared to the peripapillary retinal nerve fiber layer (PRNFL). This was performed by comparing their area under the curve (AUC) sensitivity and specificity.

• **METHODS:** This study is a prospective study. Two hundred ten eyes (54 eyes of 30 moderate glaucoma subjects, 59 eyes of 34 severe glaucoma subjects and 97 eyes of 50 normal subjects) were enrolled in this study. Patients underwent complete ophthalmic examination, visual field (VF) examination and also 3D optical coherence tomography (OCT) of the disc and 3D vertical (V) OCT of the macula were performed. The GCIPL and PRNFL AUC, sensitivity and specificity were performed and compared.

• **RESULTS:** A significantly thinner superior, inferior and total GCIPL and PRNFL thickness in moderate and severe glaucoma groups was detected (all $P < 0.001$). In moderate glaucoma, GCIPL showed higher sensitivity and specificity than PRNFL (only the superior half shows equal sensitivity). As regard severe glaucoma the total, superior and inferior sensitivities of the GCIPL were lower than the PRNFL. The total GCIPL specificity was lower than the PRNFL. The superior GCIPL specificity was higher than the PRNFL. The lower GCIPL specificity was equal to that of the PRNFL.

• **CONCLUSION:** The ability of the macular GC/IPL parameters to discriminate moderate and severe glaucoma is high and comparable to that of the PRNFL. A combination of both in the baseline evaluation is optimal and provides more accurate assessment of the extent of damage.

• **KEYWORDS:** moderate glaucoma; severe glaucoma; ganglion cell layer; ganglion cell inner plexiform layer; peripapillary retinal nerve fiber layer

DOI:10.3980/j.issn.1672-5123.2016.3.03

Citation:Asaad A. Ghanem, Dalia Sabry, Rania Kamel, Ayman Abd El-Ghafar. Glaucomatous changes in macular ganglion cell detected by spectral domain optical coherence tomography: comparison with peripapillary retinal nerve fiber layer. *Guoji Yanke Zazhi(Int Eye Sci)* 2016;16(3):409-415

INTRODUCTION

Glaucoma is a neurodegenerative disease associated with progressive loss of retinal ganglion cell layer (GCL). The goal of glaucoma management is to slow down the rate of progressive neural losses to preserve visual function during the patient's lifetime^[1-5].

Optical coherence tomography (OCT) is an optical imaging technique that provides quantitative measurements of retinal thickness alterations associated with retinal diseases. OCT provide maps of normal macular and peripapillary retinal nerve fiber layer (PRNFL) thickness^[6].

Because glaucoma primarily affects retinal ganglion cells and their axons, OCT studies have so far mostly used PRNFL thickness measurements to detect glaucoma and its progression^[7-8] given its high reproducibility^[9-10] and diagnostic ability to distinguish normal and diseased eyes^[11]. Recent studies have shown that the macular ganglion cell-inner plexiform layer (GCIPL) complex thickness also has a good glaucoma discriminating power that is comparable to that of the PRNFL and that GCL loss could be detected even in eyes with pre-perimetric glaucoma^[12-16]. It has been suggested that the macular GCL thickness may be the most relevant parameter to measure in glaucoma^[17-18].

The present study was performed on patients with moderate and severe glaucoma where the damage is well established in different layers. The aim was to detect the extent of damage caused by moderate and severe glaucoma on GCIPL and to evaluate the diagnostic performance of this layer compared to the PRNFL. This was performed by comparing their area under the curve (AUC) sensitivity and specificity.

SUBJECTS AND METHODS

Study Design This was a prospective randomized study. After explaining the details of the study, we obtained written informed consent from all patients before enrollment. The study was approved by Nokhba center for eye surgery and laser subepithelial keratomileusis (LASIK), trust ethics committee and was carried out in accordance with the Declaration of Helsinki (1989) of the world medical association.

Patients Patients with moderate glaucoma visual field (VF) mean deviation (MD) > -6 and < -12 decibel (dB) and severe glaucoma (VF MD > -12) were recruited from the Glaucoma Clinic, Mansoura Ophthalmic Center from Sep. 2013 to Feb. 2014.

We prospectively recruited 210 eyes (54 eyes of 35 moderate glaucoma subjects, 59 eyes of 34 severe glaucoma subjects and 97 eyes of 50 normal subjects). Eight patients had one eye with moderate glaucoma and the other with severe glaucoma. Patients with clinical diagnoses of open-angle glaucoma (OAG) made by an attending ophthalmologist were prospectively invited to be enrolled in the study if they met the following criteria: age >40y, OAG, visual acuity >6/60, VF MD indicating moderate (MD > -6 and < -12 dB) or severe glaucoma (MD > -12 dB).

Every patient was assessed by two of the authors. Every patient underwent a thorough eye examination on the day of

imaging, including automated refraction, unaided (UAVA) and best corrected visual acuity (BCVA) measurement on Landolt chart. Then visual acuity was converted into logarithm of minimum angle of resolution (logMAR), measurement of intraocular pressure (IOP) using Goldmann applanation tonometer, gonioscopy, slit-lamp examination, dilated fundus examination a 78 diopter (D). Visual field examination was repeated with the Humphrey Field Analyzer central 24-2 threshold (Humphrey field analyzer II; Carl Zeiss Meditec, Germany) to confirm the presence and staging of glaucoma. Exclusion criteria were: 1) refractive error ± 6.0 D and astigmatism ± 3 D; 2) eyes with evidence of retina 1 or neurologic diseases; 3) prior ocular surgery or laser therapy; 4) anterior or posterior segment inflammation; 5) patients conditions that may lead to reduction of sensitivity with misleading reduction in MD (e.g. cataract, corneal opacities, hazy media, high refractive errors); 6) eyes with consistently unreliable VFs (defined as false negative >33%, false positive >33%, and fixation losses >20%) were excluded from the study. Also, pattern standard deviation (PSD) and glaucoma hemifield test (GHT) were used to ensure localized glaucomatous field defects. All patients had at least 1 prior VF examination before being enrolled in the study.

Optical Coherence Tomography Imaging OCT scanning was performed using Topcon 3D OCT-2000 Version 8.10 (Topcon, Tokyo, Japan) to acquire 3D macular cube (V)-Scan (7.0mm \times 7.0mm-512 \times 128) and 3D optic disc cube (optic disc cube 6.0 \times 6.0mm-512 \times 128) scans in each qualifying eye. Scans were performed by one of the authors. An internal fixation target was used to improve reproducibility. Pupil dilation with tropicamide 1% and phenylephrine 2.5% was done prior to scanning. Only good-quality scans, defined as scans with image quality 40 or more (default good image quality is 30), without RNFL discontinuity or misalignment, involuntary saccade or blinking artifacts, and absence of algorithm segmentation failure on careful visual inspection, were used for analysis. Seven eyes with glaucoma were excluded because of repeated segmentation failure caused by low signal strength.

The glaucoma analysis of the disc and PRNFL were performed using the following scan protocol: scan pattern 3D, scan length 6.0 \times 6.0 mm, scan resolution 512 \times 128 pixels and fixation disc. The cube consists of 50 000 A-Scans per second centered on the optic disc. To ensure adequate centration the disc modify menu was opened and modify (Point 7) option was selected. Seven green points appear at the device predetermined disc boundaries. The points were separately dragged at the actual disc boundaries if there was any deviation. Then modification was completed by pressing "Exit Modify". The changes were saved before pressing on report button. The PRNFL thickness measurement was calculated using a peripapillary circle 3.4 mm in diameter. Average PRNFL thickness, thickness in the superior and inferior halves, quadrants and clock-hour sectors are provided in the

print out. The deviation from a normative database is provided in a color-coded scheme. PRNFL pseudo color thickness maps and significance maps for the 6.0×6.0 mm area are also provided. Disc parameters used in this research were obtained from the same scan. The print out also include disc topography that include; numerical values of different optic nerve head (ONH) parameters, a horizontal disc tomogram, a graph representing the rim disc ratio (R/D ration) in the four quadrants and color photo of the disc with a superimposed two circles: green circle (indicates the disc margin) and red circle (indicates the cup margin). In our research we used the numerical values of the rim area (RA), vertical cup disc ratio (VCDR) and the cup disc ration (CDR).

Macular GCL assessment was performed by the following scan protocol: scan pattern 3D (V), scan length 7.0×7.0 mm, scan resolution 512×128 pixels and fixation macula. The cube consists of 50 000 A-Scans per second centered on the fovea. The reports print out include the following items: color fundus image and vertical macular tomogram on the top beside each other, below them are the thickness map, significance map, average thickness and asymmetry map arranged in the same order from top to bottom; each one of them show 3 parameters which are from left to right those of RNFL thickness (retinal nerve fiber layer thickness and we refer to it as MNFL), GCL+ (which corresponds to the GCIPL thickness) and GCL++ (which corresponds to MNFL + GCIPL thickness) respectively. The GCL++ is referred to as ganglion cell complex (GCC). The thickness map shows 7.0×7.0 mm color coded map. The significance map shows 10×10 grid comparison maps covering 6.0×6.0 mm area of the macula. The comparison result is displayed with color in legend placed in right and the background image is red free image. The average thickness presents three numbers the top is "Superior" which means average thickness in the upper half, the middle is "Inferior" which means average thickness in the lower half and the bottom is the total. Each average thickness is compared to the normative data and displayed with the color in the legend placed in the right. The asymmetry map shows from left to right subtraction thickness maps covering 6.0×6.0 mm area of macula. The subtraction is performed between two points which symmetrically lie with respect to the center horizontal line. Blue color means that the thickness of the point is thinner than that of the corresponding one.

At least two good quality scans for the disc and the macula were analyzed for each to ensure reproducible results. Two authors analyzed the scans separately (Sabry D and Kamel R). Investigators were masked to the diagnosis.

Figure 1 shows the vertical macular scan, the thickness map, the significance map, the average thickness and the asymmetry map of a normal subject (A), a patient with moderate glaucoma (B) and a patient with severe glaucoma (C).

Statistical Analysis Data entry and statistical analyses were performed using SPSS (statistical package of social sciences) version 16.0 (SPSS Inc., Chicago, IL, USA). Normality of

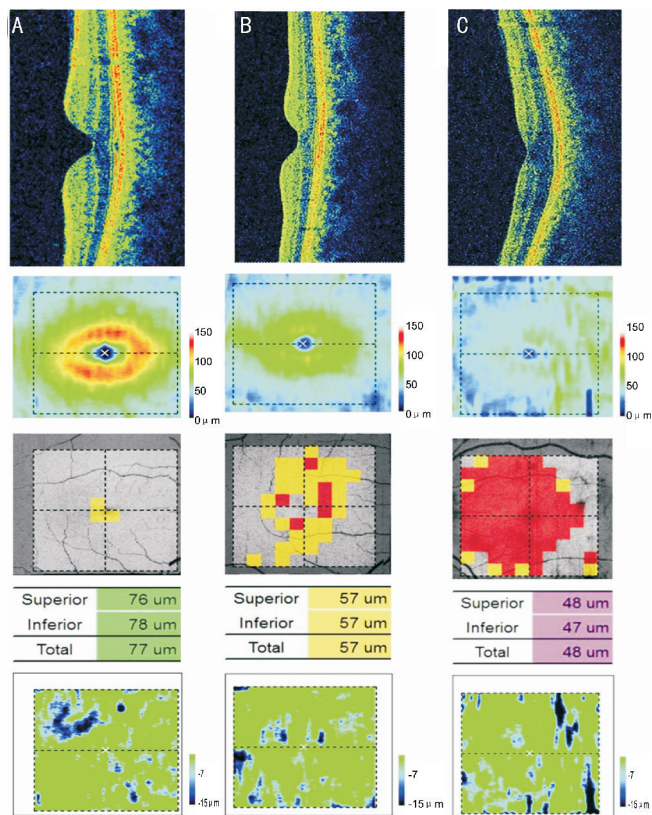


Figure 1 Changes of inner macular layers thickness with the progression of glaucoma Column A is of a normal subject, Column B is of a patient with moderate glaucoma and Column C is of patient with severe glaucoma. Each column shows from above downwards; the vertical macular scan, the thickness map, the significance map, the average thickness and the asymmetry map of a normal subject (left) and a patient with severe glaucoma (right). The average thickness shows progressive thinning of the inner macular layers with the progress of glaucoma.

data was first tested by one sample K-S (Kolmogorov-Smirnov) test. Parametric data were expressed in mean ± standard deviation. Non parametric data were expressed in median, minimum and maximum. In addition, one way ANOVA was used to compare means for normal, moderate and severe glaucomatous groups. Also, Kruskal-Wallis test was used to compare non parametric continuous variables in three different glaucomatous groups. The diagnostic accuracy of each GCIPL, RNFL parameters to differentiate between normal, moderate and severe glaucomatous eyes was determined by computing the AUC, sensitivity and specificity and cutoff values. $P < 0.05$ was considered as statistically significant.

RESULTS

Fifty-four eyes from 35 patients with moderate glaucoma, 59 eyes from 34 patients with severe glaucoma and 97 eyes from 50 normal subjects were enrolled. Patient demographic and clinical data are summarized in Table 1.

Figure 1 Column A is of a normal subject, Column B is of a patient with moderate glaucoma and Column C is of patient with severe glaucoma. Each column shows from above downwards; the vertical macular scan, the thickness map, the

Table 1 Patient demographics and clinical data

Variables	Normal subjects	Moderate glaucoma		Severe glaucoma		
		Mean±SD	P ¹	Mean±SD	P ²	P ³
Number of eyes (patients)	97 (50)	54 (35)		59 (34)		
Age (a)	54.76±7.06	55.89±8.9	0.27	56.36±10.68	0.19	0.61
Gender (F/M)	49/48	25/10		39/20		
logMAR BCVA	0.05±0.13	0.06±0.97	0.41	0.08±0.11	0.02	0.04
Spherical equivalent (D)	-0.73±2.04	-0.91±2.16	0.84	-0.83±2.31	0.12	0.48
IOP (mm Hg)	14.2±2.5	13.91±2.2	0.24	13.4±1.9	0.15	0.84
Humphrey field analyzer II						
MD (dB)	0.53±0.9	-8.3±2.1	<0.001	-16.03±2.75	<0.001	<0.001
PSD (dB)	1.79±0.81	7.65±2.1	<0.001	14.45±3.26	<0.001	<0.001

SD; Standard deviation; BCVA; Best corrected visual acuity; IOP; Intraocular pressure; MD; Mean deviation; PSD; Pattern standard deviation; P value is considered significant if P<0.05; ¹Value for comparing normal and moderate glaucoma group; ²Value for comparing normal and severe glaucoma group; ³Value for comparing moderate and severe glaucoma group.

Table 2 Total, superior and inferior macular GCIPL and PRNFL in the normal, moderate and severe glaucoma groups

OCT parameters (mean±SD)	Normal	Moderate glaucoma	P ¹	Sever glaucoma	P ²	P ³
Total GCIPL	67.97±2.13	57.63±2.07	<0.001	52.53±2.76	<0.001	<0.001
Superior GCIPL	68.30±1.98	58.78±2.66	<0.001	52.25±2.92	<0.001	<0.001
Inferior GCIPL	68.21±2.51	58.46±1.89	<0.001	53.56±3.37	<0.001	<0.001
Total PRNFL	103.16±2.7	93.43±3.41	<0.001	69.92±9.07	<0.001	<0.001
Superior PRNFL	125.23±5.73	106.13±6.77	<0.001	74.05±12.48	<0.001	<0.001
Inferior PRNFL	130.48±5.24	108.11±9.86	<0.001	71.47±9.73	<0.001	<0.001

GCIPL; Ganglion cell/inner plexiform layer; PRNFL; Peripapillary retinal nerve fiber layer; OCT; Optical coherence tomography; SD; Standard deviation. P Value is considered significant if P<0.05. ¹Value for comparing normal and moderate glaucoma group. ²Value for comparing normal and severe glaucoma group. ³Value for comparing moderate and severe glaucoma group.

Table 3 Optic nerve head vertical cup disc ratio, cup disc ratio and rim area in normal, moderate and sever glaucoma groups

Stage of glaucoma		VCDR	CDR	RA (μm)	P ¹	P ²
Normal	Median	0.45	0.26	1.4		
	Minimum	0.3	0.1	0.8		
	Maximum	0.6	0.7	2.1		
Moderate glaucoma	Median	0.64	0.5	0.96	<0.001	
	Minimum	0.5	0.2	0.84	<0.001	
	Maximum	0.9	0.7	1.6	<0.001	
Severe Glaucoma	Median	0.9	0.7	0.59	<0.001	<0.001
	Minimum	0.6	0.3	0.3	<0.001	<0.001
	Maximum	1.0	0.8	1.2	<0.001	<0.001

VCDR; Vertical cup disc ratio; CDR; Cup disc ratio; RA; Rim area. P Value is considered significant if P<0.05; ¹Value for comparing normal with moderate and severe glaucoma groups; ²Value for comparing normal and severe glaucoma group.

significance map, the average thickness and the asymmetry map of a normal subject (left) and a patient with severe glaucoma (right).

The comparison of total, superior and inferior GCIPL and PRNFL thickness in normal, moderate and severe glaucoma groups are shown in Table 2. All layers showed significant thinning when compared to normal in both moderate and severe glaucoma groups (all P<0.001).

The comparison of VCDR, CDR and RA in normal, moderate and severe glaucoma groups are shown in Table 3. The VCDR

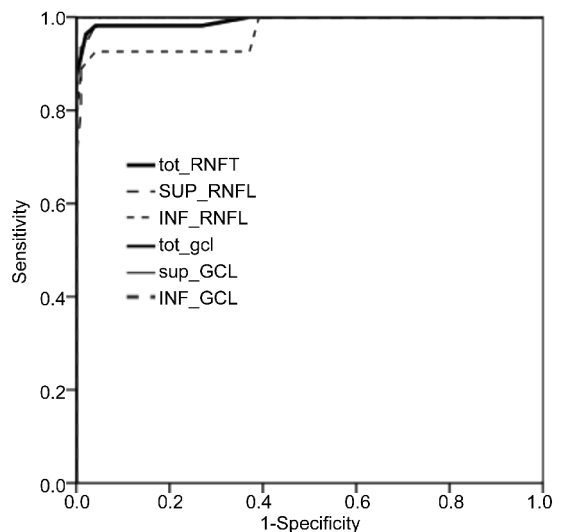


Figure 2 ROC curve showing sensitivities and specificities of GCIPL and PRNFL thickness as a diagnostic test for moderate glaucoma versus normal.

and CDR showed a significantly large cupping and the RA was significantly thinner in both moderate and severe glaucoma groups when compared to normal (all P<0.001).

Sensitivities, specificities, cutoff points and area under the curve (AUC) for different GCIPL and PRNFL thickness parameters evaluated in the study are listed in Table 4 for moderate glaucoma versus normal and Table 5 for severe

Table 4 Diagnostic accuracy of GCIPL and PRNFL in moderate glaucoma versus normal

OCT parameters	AUC	Cutoff point (μn)	Sensitivity	Specificity
Total GCIPL	1.000	63.5	100	100
Superior GCIPL	1.000	64.5	100	99
Inferior GCIPL	1.000	64.5	100	99
Total PRNFL	0.993	99.5	98	95
Superior PRNFL	0.996	117.5	100	94
Inferior PRNFL	0.970	122.5	92	95

Table 5 Diagnostic accuracy of GCIPL and PRNFL in severe glaucoma versus moderate

OCT parameters	AUC	Cutoff point (μn)	Sensitivity	Specificity
Total GCIPL	0.934	55.5	89	86
Superior GCIPL	0.944	55.5	88	89
Inferior GCIPL	0.919	56.5	86	89
Total PRNFL	0.997	89.5	100	87
Superior PRNFL	0.998	97.5	100	87
Inferior PRNFL	0.998	97.5	100	89

OCT;Optical coherence tomography;AUC;Area under the curve;GCIPL;Ganglion cell/inner plexiform layer;PRNFL;Peripapillary retinal nerve fiber layer. *P* Value is considered significant if $P < 0.05$.

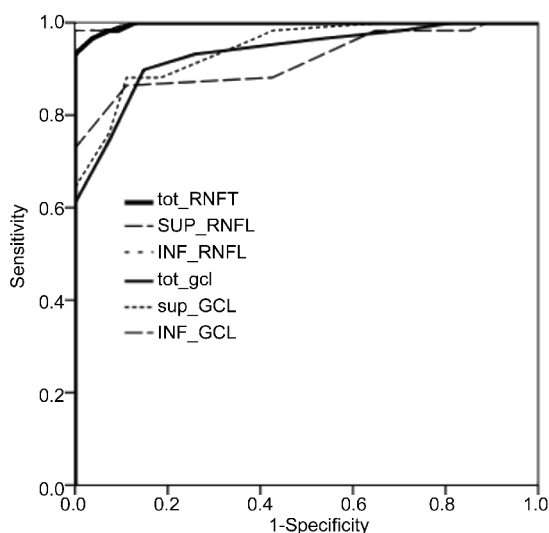


Figure 3 ROC curve showing sensitivities and specificities of GCIPL and PRNFL thickness as a diagnostic test for severe glaucoma versus moderate glaucoma.

glaucoma versus moderate. In moderate glaucoma, GCIPL showed higher sensitivity and specificity than PRNFL (only the superior PRNFL showed equal sensitivity to the superior GCIPL). As regard severe glaucoma the total, superior and inferior sensitivities of the GCIPL were lower than the PRNFL. The total GCIPL specificity was lower than the PRNFL. The superior GCIPL specificity was higher than the PRNFL. The lower GCIPL specificity was equal to that of the PRNFL.

DISCUSSION

The loss of retinal ganglion cells in glaucomatous eyes traditionally has been judged on the basis of the thinning of the PRNFL and the RA of the ONH and VF defects^[1,19-21]. Recent advances in OCT technology have enabled a more precise structural assessment of the macular region. Recently,

GCL analysis was developed as an additional tool for assessing structural change in glaucoma by detecting and measuring the thickness of the GCIPL. The GCL analysis is based on the histologic observation that macular GCIPL is topographically less variable among normal individuals than PRNFL and ONH^[22-24], which makes normal macular GCIPL parameters easier to identify and deviations from normal easier to detect and quantify^[24-27].

Most of the studies performed on the glaucoma diagnostic ability of the GCL were done on patients with early and preperimetric glaucoma. Some of these studies suggested that the ability of macular GCIPL to discriminate normal eyes and eyes with early glaucoma is high and comparable to that of the PRNFL and ONH parameters^[16,27-28]. Others suggested that the glaucoma diagnostic ability of GCIPL differs according to the Location of VF loss^[29]. Another study found that in eyes with single-hemifield damage, the retinal blood flow is significantly reduced in corresponding hemisphere which showed associated thinning of the PRNFL and GCIPL in that hemisphere^[30]. All these researches suggest that diagnostic ability of the GCIPL in early glaucoma is still under investigation.

We performed our study on patients with moderate and severe glaucoma (defined as visual field MD > -6 and > -12 dB respectively) where the damage is well established in different layers. The aim is to evaluate the effect of moderate and severe glaucoma on the GCIPL and the diagnostic performance of this layer compared to the PRNFL.

In the current study we didn't perform any manual segmentation or thickness mapping of the central retinal and all parameters used were automatically calculated by the device. Although these parameters were automatically compared by the device to its normative database, any abnormality was only displayed as color coded change. So we

compared the numbers obtained to our normal control group. As expected, the ONH parameters (VCDR, CDR and RA) showed significant changes when compared to normal subjects (all showed $P < 0.001$). Also, on comparing moderate to severe glaucoma, significant changes were detected (all showed $P < 0.001$).

Comparing the total, superior and inferior GCIPL and PRNFL in moderate and severe glaucoma versus normal, and in severe glaucoma versus moderate, showed significant changes ($P < 0.001$). The significant affection of GCIPL demonstrates the damage caused in this layer by the disease.

As regard the AUC we compared GCIPL and PNFL of moderate glaucoma to normal and severe glaucoma to moderate. The aim was to avoid the diagnostic bias caused by comparing a very advanced stage with normal and to detect the cutoff point that discriminate moderate glaucoma from normal and severe glaucoma from moderate.

In moderate glaucoma, the superior, inferior and total GCIPL showed higher sensitivity and specificity than PRNFL (apart from the superior PRNFL that showed equal sensitivity to the superior GCIPL). The high diagnostic performance of both GCIPL and PRNFL at this stage can be explained by large gap between normal subjects and patients with moderate glaucoma.

As regard severe glaucoma the total, superior and inferior sensitivities of the GCIPL were lower than the PRNFL. The total GCIPL specificity was lower than the PRNFL. The superior one was higher than the PRNFL. The lower one was equal to that of the PRNFL.

In glaucoma the damage starts at the GCL and then proceeds to the PRNFL that can explain the higher sensitivity of GCIPL in moderate glaucoma. In severe glaucoma this is not the case. This may be explained by the fact that the PRNFL measurement is from all-around the fundus which is globally affected at this stage. However the GCIPL measurement is from the central 6 mm cube that shows preserved central VF till late in the disease. This is consistent with the finding detected by a previous study that found the glaucoma diagnostic ability of GCIPL differs according to the Location of VF loss. They found that the GCIPL parameters were more valuable than the PRNFL parameters for detecting glaucoma in eyes with parafoveal VF loss, and the PRNFL parameters were better than the GCIPL parameters for detecting glaucoma in eyes with peripheral VF loss^[28].

With the advancement of OCT technology it is now possible to follow the glaucoma progression and effect of therapy on the remaining the GCIPL. It is also possible to develop clear cutoff points that discriminate different stages. Accordingly it is recommended to use of the GCL thickness as one of the most important and basic parameters in the evaluation of moderate and severe glaucoma.

There are scant data in the literature about the thickness of the GCL in moderate and severe glaucoma. However we think the rapid advancement of OCT technology will soon provide accurate segmentation and measurement of the individual

layers of the macula. This will provide a solid normative data and also classification of glaucomatous damage will soon be established depending on clear cutoff points between different stages.

The ability of the macular GCIPL parameters to discriminate moderate and severe glaucoma is high and comparable to that of the PRNFL. A combination of both in the baseline evaluation is optimal and provides more accurate assessment of the extent of damage.

REFERENCES

- 1 Quigley HA, Dunkelberger GR, Green WR. Retinal ganglion cell atrophy correlated with automated perimetry in human eyes with glaucoma. *Am J Ophthalmol* 1989;107(5):453-464
- 2 Medeiros FA, Alencar LM, Zangwill LM, Bowd C, Sample PA, Weinreb RN. Prediction of functional loss in glaucoma from progressive optic disc damage. *Arch Ophthalmol* 2009;127(10):1250-1256
- 3 Hood DC, Kardon RH. A framework for comparing structural and functional measures of glaucomatous damage. *Prog Retin Eye Res* 2007;26(6):688-710
- 4 Harwerth RS, Carter-Dawson L, Smith EL 3rd, Barnes G, Holt WF, Crawford ML. Neural losses correlated with visual losses in clinical perimetry. *Invest Ophthalmol Vis Sci* 2004;45:3152-3160
- 5 Kass MA, Heuer DK, Higginbotham EJ, Johnson CA, Keltner JL, Miller JP, Parrish RK 2nd, Wilson MR, Gordon MO. The Ocular Hypertension Treatment Study: a randomized trial determines that topical ocular hypotensive medication delays or prevents the onset of primary open-angle glaucoma. *Arch Ophthalmol* 2002;120(6):701-713; discussion 829-830
- 6 Chan A, Duker JS, Ko TH, Fujimoto JG, Schuman JS. Normal macular thickness measurements in healthy eyes using Stratus optical coherence tomography. *Arch Ophthalmol* 2006;124(2):193-198
- 7 Leung CK, Cheung CY, Weinreb RN, Qiu K, Liu S, Li H, Xu G, Fan N, Pang CP, Tse KK, Lam DS. Evaluation of retinal nerve fiber layer progression in glaucoma: a study on optical coherence tomography guided progression analysis. *Invest Ophthalmol Vis Sci* 2010;51(1):217-222
- 8 Strouthidis NG, Fortune B, Yang H, Sigal IA, Burgoyne CF. Longitudinal change detected by spectral domain optical coherence tomography in the optic nerve head and peripapillary retina in experimental glaucoma. *Invest Ophthalmol Vis Sci* 2011;52(3):1206-1219
- 9 Budenz DL, Fredette MJ, Feuer WJ, Anderson DR. Reproducibility of peripapillary retinal nerve fiber thickness measurements with stratus OCT in glaucomatous eyes. *Ophthalmology* 2008;115(4):661-666
- 10 Mwanza JC, Chang RT, Budenz DL, Durbin MK, Gendy MG, Shi W, Feuer WJ. Reproducibility of peripapillary retinal nerve fiber layer thickness and optic nerve head parameters measured with cirrus HD-OCT in glaucomatous eyes. *Invest Ophthalmol Vis Sci* 2010;51(11):5724-5730
- 11 Mwanza JC, Oakley JD, Budenz DL, Anderson DR; Cirrus Optical Coherence Tomography Normative Database Study Group. Ability of cirrus HD-OCT optic nerve head parameters to discriminate normal from glaucomatous eyes. *Ophthalmology* 2011;118(2):241-248
- 12 Garas A, Vargha P, Hollo G. Diagnostic accuracy of nerve fibre layer, macular thickness and optic disc measurements made with the RTVue-100 optical coherence tomograph to detect glaucoma. *Eye (Lond)* 2011;25(1):57-65
- 13 Kim NR, Lee ES, Seong GJ, Kang SY, Kim JH, Hong S, Kim CY. Comparing the ganglion cell complex and retinal nerve fibre layer measurements by Fourier domain OCT to detect glaucoma in high myopia. *Br J Ophthalmol* 2011;95(8):1115-1121

- 14 Schulze A, Lamparter J, Pfeiffer N, Berisha F, Schmidtman I, Hoffmann EM. Diagnostic ability of retinal ganglion cell complex, retinal nerve fiber layer, and optic nerve head measurements by Fourier-domain optical coherence tomography. *Graefes Arch Clin Exp Ophthalmol* 2011; 249(7):1039–1045
- 15 Tan O, Chopra V, Lu AT, Schuman JS, Ishikawa H, Wollstein G, Varma R, Huang D. Detection of macular ganglion cell loss in glaucoma by Fourier-domain optical coherence tomography. *Ophthalmology* 2009; 116(12):2305–2314
- 16 Lisboa R, Paranhos A Jr, Weinreb RN, Zangwill LM, Leite MT, Medeiros FA. Comparison of different spectral domain OCT scanning protocols for diagnosing preperimetric glaucoma. *Invest Ophthalmol Vis Sci* 2013;54(5):3417–3425
- 17 Nakano N, Hangai M, Nakanishi H, Mori S, Nukada M, Kotera Y, Ikeda HO, Nakamura H, Nonaka A, Yoshimura N. Macular ganglion cell layer imaging in preperimetric glaucoma with speckle noise-reduced spectral domain optical coherence tomography. *Ophthalmology* 2011;118(12):2414–2426
- 18 Quigley HA. Number of people with glaucoma worldwide. *Br J Ophthalmol* 1996;80(5):389–393
- 19 Airaksinen PJ, Tuulonen A, Alanko HI. Rate and pattern of neuroretinal rim area decrease in ocular hypertension and glaucoma. *Arch Ophthalmol* 1992;110(2):206–210
- 20 Sommer A, Katz J, Quigley HA, Miller NR, Robin AL, Richter RC, Witt KA. Clinically detectable nerve fiber atrophy precedes the onset of glaucomatous field loss. *Arch Ophthalmol* 1991;109(1):77–83
- 21 Quigley HA, Addicks EM, Green WR. Optic nerve damage in human glaucoma. III. Quantitative correlation of nerve fiber loss and visual field defect in glaucoma, ischemic neuropathy, papilledema, and toxic neuropathy. *Arch Ophthalmol* 1982;100(1):135–146
- 22 Curcio CA, Allen KA. Topography of ganglion cells in human retina. *J Comp Neurol* 1990;300(1):5–25
- 23 Meshi A, Goldenberg D, Armarnik S, Segal O, Geffen N. Systematic review of macular ganglion cell complex analysis using spectral domain optical coherence tomography for glaucoma assessment. *World J Ophthalmol* 2015;5(2):86–98
- 24 Fortune B, Cull G, Reynaud J, Wang L, Burgoyne CF. Relating Retinal Ganglion Cell Function and Retinal Nerve Fiber Layer (RNFL) Retardance to Progressive Loss of RNFL Thickness and Optic Nerve Axons in Experimental Glaucoma. *Invest Ophthalmol Vis Sci* 2015;56(6):3936–3944
- 25 Kotowski J, Folio LS, Wollstein G, Ishikawa H, Ling Y, Bilonick RA, Kagemann L, Schuman JS. Glaucoma discrimination of segmented cirrus spectral domain optical coherence tomography (SD-OCT) macular scans. *Br J Ophthalmol* 2012;96(11):1420–1425
- 26 Takayama K, Hangai M, Durbin M, Nakano N, Morooka S, Akagi T, Ikeda HO, Yoshimura N. A novel method to detect local ganglion cell loss in early glaucoma using spectral – domain optical coherence tomography. *Invest Ophthalmol Vis Sci* 2012;53(11):6904–6913
- 27 Mwanza JC, Durbin MK, Budenz DL, Sayyad FE, Chang RT, Neelakantan A, Godfrey DG, Carter R, Crandall AS. Glaucoma diagnostic accuracy of ganglion cell – inner plexiform layer thickness: comparison with nerve fiber layer and optic nerve head. *Ophthalmology* 2012;119(6):1151–1158
- 28 Kim KE, Yoo BW, Jeoung JW, Park KH. Long – Term Reproducibility of Macular Ganglion Cell Analysis in Clinically Stable Glaucoma Patients. *Invest Ophthalmol Vis Sci* 2015;56(8):4857–4864
- 29 Shin HY, Park HL, Jung K, Choi J, Park CK. Glaucoma diagnostic ability of ganglion cell – inner plexiform layer thickness differs according to the location of visual field loss. *Ophthalmology* 2014;121(1):93–99
- 30 Sehi M, Goharian I, Konduru R, Tan O, Srinivas S, Sadda SR, Francis BA, Huang D, Greenfield DS. Retinal blood flow in glaucomatous eyes with single – hemifield damage. *Ophthalmology* 2014; 121(3):750–758