

Successful cataract surgery on an eye with preexisting posterior capsule defect due to pars plana vitrectomy

Zsuzsanna Szijártó, Zsolt Biró

Department of Ophthalmology, University of Pécs, Hungary
Correspondence to: Zsuzsanna Szijártó. 7624 Pécs Ifjúság st. 13. Hungary. zsuzsana.szijarto@aok.pte.hu
Received: 2010-05-05 Accepted: 2010-08-11

Abstract

- **AIM:** To evaluate the effect of operation on an eye of a 54-year-old female who developed a posterior capsular hole during pars plana vitrectomy for diabetic retinopathy.
- **METHODS:** We performed phacoemulsification using the "inside-out hydrodelineation" technique.
- **RESULTS:** The procedure was successful; a posterior chamber intraocular lens (PC-IOL) was also implanted.
- **CONCLUSION:** Accurate diagnosis by meticulous examination after maximal mydriasis, and a detailed discussion with the patient are required to successfully care for a patient with a preexisting posterior capsule defect.
- **KEYWORDS:** inside-out hydrodelineation; phacoemulsification; posterior capsule defect

DOI: 10.3969/j.issn.1672-5123.2010.09.005

Szijártó Z, Biró Z. Successful cataract surgery on an eye with preexisting posterior capsule defect due to pars plana vitrectomy. *Int J Ophthalmol (Guoji Yanke Zazhi)* 2010;10(9):1657-1658

INTRODUCTION

The recommended surgical strategy for eyes with preexisting posterior capsule defect is to provide a protective cortex cushion during nucleus removal by avoiding cortical-cleaving hydrodissection and rotation of the nucleus^[1,2]. With conventional hydrodissection, there is a high risk of enlarging the preexisting rupture and subsequently dropping lens materials into the vitreous. This can be avoided by the "inside-out hydrodelineation" technique, where the fluid is precisely injected between the cortex and the nucleus^[3], after sculpting a deep groove in the middle of the lens.

CASE REPORT

A 54-year-old woman underwent pars plana vitrectomy on the right eye for diabetic retinopathy. Soon after surgery, her vision deteriorated and the lens became opaque. Slit-lamp examination revealed a ruptured posterior capsule and lens pearls bulging into the vitreous through the posterior capsule defect (Figure 1).

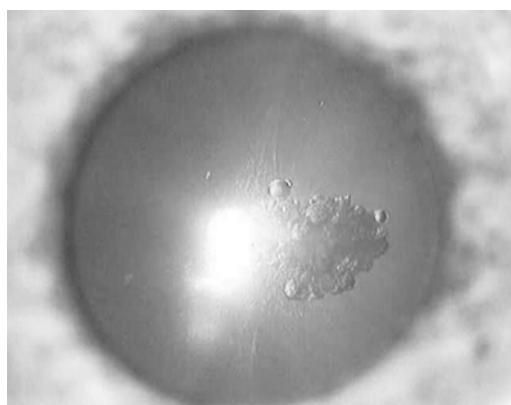


Figure 1 Ruptured posterior capsule and lens pearls bulging into the vitreous just behind the lens.

Surgical Technique After topical anaesthesia, the anterior chamber was filled up with ophthalmic viscosurgical device and a continuous curvilinear capsulorhexis was performed with forceps. We avoided hydrodissection and rotation of the nucleus. With very low vacuum, a central trench was sculpted. Delineation was performed through the groove by gently injecting fluid from inside to outside, following the technique of Vasavada *et al*^[4]. The central nucleus and the epinucleus were easily removed. The remaining cortex bowl gave protection and safety for the posterior capsule during the whole procedure. Unfortunately, because of the extension of posterior capsule lesion to the periphery during cortex removal, we could not convert the preexisting lesion to a continuous posterior capsular rhexis, which was our original plan, and would have been the ideal solution. Because of this, we implanted the posterior chamber intraocular lens (PC-IOL) in the ciliary sulcus, instead of the capsular bag.

DISCUSSION

Posterior capsule weakness can be found among infants and small children with congenital posterior polar cataract, where an existing defect in the posterior capsule is well known^[4,5]. Posterior polar cataracts in adults also present greater surgical risk, and therefore should be differentiated from posterior cortical cataract. Other types of preexisting posterior capsule breaks were observed after perforating ocular injury^[6], and in traumatic cataract with intact anterior capsule^[7]. Direct mechanical injury of the posterior lens capsule in vitrectomized eyes occurs rarely. We could not find any case

mentioned in the literature, despite the fact that it is not entirely unlikely when cataract develops shortly after pars plana vitrectomy.

The anatomical situation in this case is worse compared to the posterior polar cataract, because there is no surrounding round intact posterior capsular rim, but vitreous lenticular support is also absent, thereby increasing the risk of dropping the nucleus.

Our case can be considered successful as no dropped nucleus occurred despite the preexisting posterior capsule defect, and because a PC-IOL could be implanted, although ideally it would have been preferable if the posterior capsule defect had been converted to a posterior capsulorhexis and the PC-IOL had been implanted into the capsular bag.

Accurate diagnosis by meticulous examination after maximal mydriasis, and a detailed discussion with the patient are required to successful care for a patient with a preexisting posterior capsule defect. Early intervention is preferred before the lens becomes denser or mature, requiring more phaco power and worsening visualisation during surgery. Furthermore, spontaneous nucleus drop may occur due to enlargement of the (originally usually tiny) posterior capsule defect from swelling of the crystalline lens.

REFERENCES

- 1 Vasavada A, Singh R. Phacoemulsification in eyes with posterior polar cataract. *J Cataract Refract Surg* 1999;25(2):238-245
- 2 Vasavada A, Singh R. Surgical techniques for difficult cataracts. *Curr Opin Ophthalmol* 1999;10(1):46-52
- 3 Vasavada AR, Raj SM. Inside-out delineation. *J Cataract Refract Surg*

2004;30(6):1167-1169

4 Vasavada AR, Praveen MR, Nath V, Dave K. Diagnosis and management of congenital cataract with preexisting posterior capsule defect. *J Cataract Refract Surg* 2004;30(2):403-408

5 Vasavada AR, Praveen MR, Dholakia SA, Trivedi RH. Preexisting posterior capsule defect progressing to white mature cataract. *JAAPOS* 2007;11(2):192-194

6 Vaypajee RB, Angra SK, Honavar SG, Titiyal JS, Sharma YR, Sakhuja N. Pre-existing posterior capsule breaks from perforating ocular injuries. *J Cataract Refract Surg* 1994;20(3):291-294

7 Nanavaty MA, Mehta PA, Raj SM, Vasavada AR. Diagnosis of pre-existing posterior capsule defect in traumatic white mature cataract with intact anterior capsule. *Eye (Lond)* 2006;20(8):949-951

玻璃体平坦部切除术后后囊膜缺损患者 1 例的 白内障手术治疗

Zsuzsanna Szijártó, Zsolt Biró

(作者单位:匈牙利佩奇市,佩奇大学眼科)

通讯作者:Zsuzsanna Szijártó. zsuzsana.szijarto@aok.pte.hu

摘要

目的:评价 1 例 54 岁女性糖尿病性视网膜病变患者玻璃体平坦部切除术后后囊膜缺损的手术治疗效果。

方法:我们使用"内外水轮廓分离"技术进行白内障超声乳化术对此例患者进行手术。

结果:使用后房型人工晶状体植入后,手术进展顺利。

结论:仔细散瞳检查后的精确诊断和详细讨论患者的病情,对于晶状体后囊缺损患者的成功治疗是必要的。

关键词:内外水轮廓分离;超声乳化术;后囊膜缺损